

Effects of N-Acetylcysteine on Oxidative Stress in Rats with Non-alcoholic Steatohepatitis

Suchittra Samuhasaneeto MSc*,
Duangporn Thong-Ngam MD*, Onanong Kulaputana MD, PhD*,
Suthiluk Patumraj PhD*, Naruemon Klaikeaw MD**

* Department of Physiology, Faculty of Medicine, Chulalongkorn University

** Department of Pathology, Faculty of Medicine, Chulalongkorn University

Objective: Prove the attenuated effects of N-acetylcysteine (NAC) on oxidative stress in rats with nonalcoholic steatohepatitis (NASH).

Material and Method: Male Sprague-Dawley rats were randomly divided into five groups. Group 1 (normal control) was fed regular dry rat chow (RC) for 6 weeks. Group 2 (NASH) was fed 100% fat diet for 6 weeks. Group 3-5 were fed 100% fat diet for 6 weeks, and then switched to RC alone (NASH+diet; group 3), to RC+20 mg/kg/day of NAC orally (NASH+diet+NAC₂₀; group 4) or to RC+500 mg/kg/day of NAC orally (NASH+diet+NAC₅₀₀; group 5) for 4 weeks, respectively. They were sacrificed to collect blood and liver samples at the end of the present study.

Results: Levels of total glutathione (GSH), serum cholesterol, and hepatic malondialdehyde (MDA) were increased significantly in the NASH group compared with normal control. Liver histopathology from group 2 showed moderate to severe macrovesicular steatosis, hepatocyte ballooning, and necroinflammation. Treatment with diet or diet plus NAC reduced the levels of GSH, cholesterol, and hepatic MDA back to normal. Liver sections from group 3-5 showed a decrease in fat deposition and necroinflammation in hepatocytes. However, no differences on all variables existed between diet alone and diet plus NAC groups.

Conclusion: Our data indicate that diet or diet plus NAC treatment could attenuate oxidative stress and improve liver histopathology of NASH. However, the addition of NAC is not better than diet treatment alone.

Keywords: NASH, Steatohepatitis, N-acetylcysteine, Oxidative stress

J Med Assoc Thai 2007; 90 (4): 788-97

Full text. e-Journal: <http://www.medassocthai.org/journal>

Nonalcoholic steatohepatitis (NASH) is a chronic liver disease that occurs in patients who do not consume significant amounts of alcohol and its histology resembles that of alcoholic liver disease including macrovesicular steatosis, hepatocyte necrosis, inflammation, Mallory bodies, and fibrosis⁽¹⁾. NASH associates with obesity, diabetes mellitus, and hyperlipidemia. As the prevalence of obesity and diabetes mellitus continues to increase, many patients will be diagnosed with NASH⁽²⁾. In initial phases, during which fat accumulates in the liver, no clinical symptoms are evident. In advanced stages, fibrosis is detectable

(eventually progressing to cirrhosis in some patients)⁽³⁾. NASH is one of the predominant types of chronic liver disease in the United States with an estimated prevalence of 5% in the general population⁽⁴⁾. Several studies have now demonstrated that this is not a benign condition, some patients with NASH progress to cirrhosis over time⁽⁵⁻⁷⁾.

Based on present concepts of pathogenesis, oxidative stress is likely involved in the progression of disease from steatosis to NASH and potentially cirrhosis. It has been shown that chronic oxidative stress, generated through the oxidation of cytotoxic free fatty acids, can lead to upregulation of cytokines⁽⁸⁾, induction of the liver cytochrome P450 enzyme 2E1 (CYP2E1), and depletion of hepatic antioxidant concentration⁽⁹⁾. In addition, enhanced lipid peroxidation leads to the

Correspondence to : Thong-Ngam D, Department of Physiology, Faculty of Medicine, Chulalongkorn University, Bangkok 10330, Thailand. Phone & Fax: 0-2256-4267, E-mail: thongngam007@yahoo.com

generation of byproducts, such as 4-hydroxynonenal (4-HNE) and malondialdehyde (MDA), which have been shown to further enhance cytokine stimulation. They are involved in hepatic stellate cell activation⁽¹⁰⁾, fibrogenesis, and enhanced extra-cellular matrix protein deposition. Seki et al have recently shown that lipid peroxidation products are elevated in NASH patients, occur more prominently in zone 3 of the liver parenchyma, and correlate directly with increasing necro-inflammatory activity and fibrosis⁽¹¹⁾.

No effective medical treatment is currently available for patients with NASH. Reduction of weight is frequently advocated but it is a difficult goal to maintain and some patients have been reported to have worsening of their liver damage with extreme weight loss^(5,12). According to concepts of pathogenesis of NASH, these might make a wise basis for the use of antioxidants or drugs that could protect hepatocytes from oxidative stress. N-acetylcysteine (NAC) is a glutathione precursor that increases glutathione levels in hepatocytes⁽¹³⁾. Increased glutathione levels, in turn, limit the production of reactive oxygen species (ROS) which cause hepatocellular injury⁽¹⁴⁾. There are two studies using NAC for treating NASH, Gulbahar et al administered NAC (1g/day) orally in 11 NASH patients for 3 months. The result showed that liver function test was improved significantly at the end of treatment period⁽¹³⁾. In 2003, the controlled study, NAC (600mg/day) was administered to NASH patients for 4 weeks. They found a significant improvement in aminotransferase levels⁽¹⁵⁾. Therefore, in the present study, the authors work with NASH, with or without treatment, using NAC, measuring the many parameters such as total glutathione, liver function, lipid profile, lipid peroxidation, and liver histopathology in rats, with NASH.

The present study was conducted to prove the hypothesis that 100% fat diet can induce NASH in rats and treatment with NAC can reduce oxidative stress and improve histology in rats with NASH.

Material and Method

Animal Preparation

Male Sprague-Dawley rats weighing 220-260 grams from the National Laboratory Animal Center, Mahidol University, Salaya, Nakorn Pathom were used. The animals were allowed to rest for a week after arrival at the Animal Center, Department of Physiology, Faculty of Medicine, Chulalongkorn University before being used in the experiment. They were kept in a controlled temperature room at 25 ± 1 °C under standard

conditions (12 hours dark:12 hours light cycle), fed regular dry rat chow *ad libitum*, and had free access to drinking water.

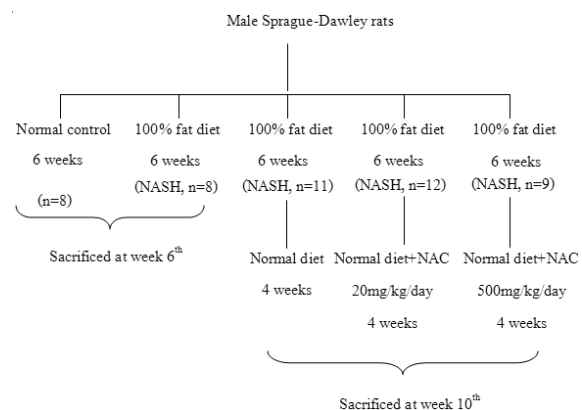
Experimental Protocols

Rats were randomly divided into five experimental groups:

Group 1: fed *ad libitum* with regular dry rat chow and drinking water for 6 weeks (Normal control group, n = 8).

Group 2: fed *ad libitum* with 100% fat diet and drinking water for 6 weeks to induce NASH (100% fat diet, NASH group, n = 8).

Group 3-5: the rats were fed with 100% fat diet for 6 weeks to induce NASH. After that, starting from week 7th, the rats were fed with regular dry rat chow (NASH + diet group, n = 11) plus 20 mg/kg/day of NAC orally (NASH + diet + NAC₂₀ group, n = 12) or 500 mg/kg/day of NAC orally (NASH+diet+NAC₅₀₀ group, n=9) respectively, for other 4 weeks. All the rats were weighed weekly. They were sacrificed to collect blood, serum, and liver samples at the end of the present study, 20 hours after the last NAC treatment. The diagram of the experiment is shown as follows.



At the end of the present study, all the rats were anaesthetized using intraperitoneal injection of an overdose (45 mg/kg BW) of sodium pentobarbital and then the abdominal walls were opened. Blood was drawn by cardiac puncture using a disposable syringe with needle No.21 and collected into two micro centrifuge tubes (tube No.1 for total glutathione assay and tube No.2 for biochemical assay). Later, the animals were sacrificed by cutting the abdominal veins. The livers were excised quickly and cleaned in iced-cold NSS. Fat and fibrous tissues were removed before the liver was weighed and kept on ice afterwards. One lobe

of the liver was collected for MDA measurement and the remaining liver was fixed in 10% formalin solution for histopathology examination.

Total Glutathione Determination

Total glutathione levels were measured using Cayman's GSH assay kit. This assay uses glutathione reductase for the quantification of GSH. The sulfhydryl group of GSH reacts with DTNB (5,5'-dithiobis-2-nitrobenzoic acid, Ellman's reagent) and produces a yellow colored 5-thio-2-nitrobenzoic acid (TNB). The mixed disulfide, GSTNB (between GSH and TNB) that is concomitantly produced, is reduced by glutathione reductase to recycle the GSH and produce more TNB. The rate of TNB production is directly proportional to this recycling reaction, which is in turn directly proportional to the concentration of GSH in the sample. Measurement of the absorbance of TNB at 405 nm provides an accurate estimation of GSH in the sample.

Hepatic malondialdehyde (MDA) determination

One lobe of the liver was removed and weighed. Then 1 gram of the tissue was placed in a test tube containing 2.25 ml of homogenization buffer (1.15% KCl) and homogenized in an icebox using a homogenizer at a rotational speed of 12,000 rpm for 1 minute. Malondialdehyde was measured from the homogenized tissue by using thiobarbituric acid reaction as described by Ohgawa et al⁽¹⁶⁾. The basic principle of the method is the reaction of one molecule of malonaldehyde and two molecules of Thiobarbituric acid (TBA) to form a red malonaldehyde-TBA complex, which can be quantitated spectrophotometrically (532 nm). MDA levels in the samples were determined by the linear regression equation from a standard curve. The content of lipid peroxide is expressed in terms of nmol of MDA/gram of wet weight and the total protein was determined by the Lowry method⁽¹⁷⁾ to correct the MDA level, which is expressed in terms of nmol/mg protein.

Histopathological examination

The remaining liver samples were fixed in 10% formalin solution at room temperature. They were processed by standard method, tissues were embedded in paraffin, sectioned at 5 mm, and stained with Hematoxylin-Eosin (H&E) and then picked up on glass slides for light microscopy. An experienced pathologist evaluated all samples while blinded to the experiment. All fields in each section were examined for grading of steatosis and necroinflammation according to Brunt et al criteria⁽¹⁸⁾.

The severity of steatosis was graded on the basis of the extent of involved parenchyma. Scored 1 = were those in which fewer than 33% of the hepatocytes were affected, scored = 2 were those in which 33-66% of the hepatocytes were affected, scored = 3 were those in which more than 66% of the hepatocytes were affected, and scored = 0 were those in which no hepatocytes were affected.

Hepatic necro-inflammation was graded from 0 to 3; score 1 (mild) = sparse or mild focal zone 3 hepatocyte injury/inflammation, score 2 (moderate) = noticeable zone 3 hepatocyte injury/inflammation, score 3 (severe) = severe zone 3 hepatocyte injury/inflammation, and score 0 = no hepatocyte injury/inflammation.

Ethical Considerations

The present study was approved by the Ethics Committee of the Faculty of Medicine, Chulalongkorn University, Bangkok, Thailand.

Statistical analysis

The data were expressed as mean \pm SEM using the SPSS version 11.5 for Windows program. Statistical comparisons between groups were analyzed by ANOVA and post hoc comparisons were done with Bonferroni correction. Differences between two groups were analyzed by unpaired t-tests. $p < 0.05$ were considered statistically significant.

Results

Body weight and general condition

The body weight at 6 weeks of rats fed with 100% fat diet was decreased when compared to the beginning (197.00 ± 8.07 g vs 438.38 ± 9.70 g, $p < 0.05$). Despite weight loss, the general condition of 100% fat diet-fed rats remained good throughout the experiment. After the first 6 weeks, rats were fed with regular dry rat chow for additional 4 weeks. The body weight was significantly increased in all groups.

Serum Biochemical Parameters

Serum biochemical parameters in the normal control and experimental groups are shown in Table 1. Serum AST and ALT were decreased significantly in 100% fat diet-fed rats compared with normal controls (AST; 53.63 ± 9.31 U/L vs 86.75 ± 4.28 U/L, ALT; 23.00 ± 1.92 U/L vs 40.13 ± 2.35 U/L, $p < 0.05$). Additionally, serum cholesterol level was significantly higher in the 100% fat diet-fed rats than that in the normal controls (94.75 ± 3.11 mg/dL vs 71.75 ± 1.84 mg/dL, $p < 0.05$), whereas there was no significant difference in serum

triglycerides between the two groups.

The analysis of serum AST level in the normal controls (86.75 ± 4.28 U/L), NASH + diet (93.00 ± 4.08 U/L), NASH + diet + NAC₂₀ (81.42 ± 2.61 U/L), and NASH + diet + NAC₅₀₀ (95.22 ± 8.18 U/L) showed no significant difference. There was no significant difference in serum ALT level among the normal controls (40.13 ± 2.35 U/L), NASH + diet (44.18 ± 1.30 U/L), NASH + diet + NAC₂₀ (39.83 ± 1.40 U/L), and NASH + diet + NAC₅₀₀ (41.89 ± 2.02 U/L). For cholesterol levels in the normal controls (71.75 ± 1.84 mg/dL), NASH + diet (70.82 ± 2.26 mg/dL), NASH + diet + NAC₂₀ (71.50 ± 1.46 mg/dL), and NASH + diet + NAC₅₀₀ (75.78 ± 2.01 mg/dL) were not statistically significant. In addition,

the result of triglyceride levels in the normal controls (90.25 ± 19.09 mg/dL), NASH + diet (121.36 ± 15.36 mg/dL), NASH + diet + NAC₂₀ (114.00 ± 5.24 mg/dL), and NASH + diet + NAC₅₀₀ (97.11 ± 10.66 mg/dL) showed no significant differences.

Total Glutathione Level in Whole Blood

The total glutathione level in whole blood in 100% fat diet-fed rats was increased significantly compared with the normal control group (2066.67 ± 93.81 μ M vs 1337.54 ± 31.48 μ M, $p < 0.05$).

Total glutathione levels in NASH + diet, NASH + diet + NAC₂₀, and NASH + diet + NAC₅₀₀ were not different compared with the normal controls ($1287.15 \pm$

Table 1. The results of body weight and serum biochemical parameters in all groups

Parameters	Normal control (n = 8)	NASH 6 weeks (n = 8)	NASH + diet (n = 11)	NASH + diet + NAC ₂₀ (n = 12)	NASH + diet + NAC ₅₀₀ (n = 9)
Body weight at the beginning (g)	239.00 \pm 2.27	245.13 \pm 0.99	246.82 \pm 1.45	241.75 \pm 1.65	245.89 \pm 1.78
Body weight at 6 weeks (g)	438.38 \pm 9.70	197.00 \pm 8.07*	183.82 \pm 4.24*	181.42 \pm 4.72*	182.00 \pm 6.55*
Body weight at 10 weeks (g)	-	-	411.73 \pm 4.91	403.50 \pm 4.97*	383.67 \pm 4.28*
AST (U/L)	86.75 \pm 4.28	53.63 \pm 9.31*	93.00 \pm 4.08	81.42 \pm 2.61	95.22 \pm 8.18
ALT (U/L)	40.13 \pm 2.35	23.00 \pm 1.92*	44.18 \pm 1.30	39.83 \pm 1.40	41.89 \pm 2.02
Cholesterol (mg/dL)	71.75 \pm 1.84	94.75 \pm 3.11*	70.82 \pm 2.26	71.50 \pm 1.46	75.78 \pm 2.01
Triglycerides (mg/dL)	90.25 \pm 19.09	147.75 \pm 32.57	121.36 \pm 15.36	114.00 \pm 5.24	97.11 \pm 10.66

* Significant difference ($p < 0.05$) compared with normal control 6 weeks
Significant difference ($p < 0.05$) compared with NASH + diet

Table 2. Effects of NAC on liver histopathology in rats with NASH: summary of the scores of steatosis and necroinflammation

Group	Number	Level of steatosis				Level of necroinflammation			
		0	1	2	3	0	1	2	3
Normal control	8	8	-	-	-	8	-	-	-
NASH	8	-	-	5	3	-	5	2	1
NASH + diet	11	11	1	-	-	10	1	-	-
NASH + diet + NAC ₂₀	12	9	3	-	-	12	-	-	-
NASH + diet + NAC ₅₀₀	9	9	-	-	-	9	-	-	-

The severity of steatosis was graded by:

0 = No steatosis

1 = Fewer than 33% of the hepatocytes were affected

2 = 33%-66% of the hepatocytes were affected

3 = More than 66% of the hepatocytes were affected

The severity of necroinflammation was graded by:

0 = No hepatocyte injury/inflammation

1 = Sparse or mild focal zone 3 hepatocyte injury/inflammation

2 = Noticeable zone 3 hepatocyte injury/inflammation

3 = Severe zone 3 hepatocyte injury/inflammation

23.27 μ M, 1332.76 \pm 23.31 μ M, and 1455.94 \pm 46.17 μ M vs 1337.54 \pm 31.48 μ M, respectively, $p > 0.05$) (Fig. 1).

Hepatic Malondialdehyde (MDA) Content

MDA was elevated significantly in the 100% fat diet-fed rats compared with that in the normal controls (209.88 \pm 43.83 nmol/mg protein vs 3.80 \pm 1.68 nmol/mg protein, $p < 0.05$).

By week 10, hepatic MDA contents of the rats in NASH + diet, NASH + diet + NAC₂₀, and NASH + diet + NAC₅₀₀ were not different from that of normal controls (3.10 \pm 0.90, 2.85 \pm 0.87, and 2.23 \pm 0.14 vs 3.80 \pm 1.68 nmol/mg protein, respectively, $p > 0.05$) (Fig. 2).

Histopathological Examination

The pathological grading for steatosis and necro-inflammation was summarized in Table 2. Liver sections from rats fed with the regular dry rat chow had shown normal morphological appearance. In rats fed with 100% fat diet for 6 weeks, all livers developed moderate to severe macrovesicular steatosis, hepatocyte ballooning, mild to moderate inflammation, and regeneration of hepatocytes. The pathological changes of liver were obviously improved in NASH + diet, NASH + diet + NAC₂₀, and NASH + diet + NAC₅₀₀ groups compared with the NASH group (Fig. 3).

Discussion

Histopathology of NASH is similar to that of alcoholic induced hepatitis with the presence of macrovesicular steatosis, hepatocyte ballooning, necro-inflammation, Mallory bodies, and fibrosis⁽¹⁾. To study the pathogenesis or therapeutic methods of NASH, there are many models that have been used such as genetic model (obese rats), methionine and choline deficient diets, high fat liquid diet, and 100% fat diet. In the present study, 100% fat diet was chosen to induce NASH in Sprague-Dawley rats as this procedure took a short-time, had no technical difficulty, and provided the same pattern pathological change as in humans.

By feeding rats with 100% fat diet, the hepatic lesions of NASH were apparent within 6 weeks. Histopathological examination showed macrovesicular steatosis, hepatocyte ballooning, Mallory bodies, and mild to moderate inflammation. One hundred percent fat diet caused mobilizing of free fatty acid (FFA) from adipose tissue and transporting into hepatocytes. In this condition, the liver failed to synthesize apolipoprotein that was used for packaging and exporting of fat from the liver, therefore triglycerides (TG) accumulated in the liver⁽¹⁹⁾. β -oxidation of FFA in hepatocytes pro-

duced reactive oxygen species (ROS) which activated lipid peroxidation⁽²⁰⁾. ROS and lipid peroxidation caused direct damage to hepatocytes by disrupting membranes, protein, and DNA^(21,22). The damage and lipid peroxidation products induced an inflammatory response.

In 100% fat diet-fed rats, body weight decreased significantly ($p < 0.05$) compared with the normal control group. Rats fed with 100% fat eat less, but derived energy similar to normal diet. Feeding 100% fat diet for 6 weeks caused a loss of body weight that may be due to a metabolic imbalance of carbohydrate, protein, and fat. After induced NASH with 100% fat diet for 6 weeks and treated with diet control or diet plus NAC, the body weight in rats with NASH increased nearly to the level of normal control group by week 10. High dose of NAC caused nausea, vomiting, and gastrointestinal disturbance⁽³⁰⁾. Therefore, in NASH + diet + NAC₅₀₀ group, the body weight was lower when compared with NASH + diet group. This may be caused by poor appendage side effects of high dose of NAC.

Serum cholesterol significantly increased, serum TG level was unchanged with 100% fat diet. 100% fat diet contained highly saturated fat which may increase blood cholesterol concentration by 15 to 25%⁽²³⁾. This result was from an increase of fat deposition in the liver that provides the increased quantities of acetyl CoA in the liver cell for production of cholesterol⁽²³⁾. The increased cholesterol was found in this experiment and had been observed in another study that used 10% lard oil and 2% cholesterol supplement adding into the standard diet⁽²⁴⁾.

Serum aspartate aminotransferases (AST) and alanine aminotransferases (ALT) are useful screening tests for detecting liver injury⁽²⁵⁾. They are found in hepatocytes and cannot diffuse out of the cells in normal situation. When the hepatocyte is injured, plasma membrane can be disrupted and the leakage through extra-cellular fluid of the enzyme occurs where they can be detected at abnormal levels in the serum⁽²⁶⁾. Several experiments found that AST and ALT increased in NASH rats^(9,24,27-29). In contrast, AST and ALT decreased significantly with 6 weeks of 100% fat diet in the present study. The decreased serum transaminases may be due to poor nutrition or hepatocyte death. Rats fed 100% with fat diet derived main energy from fat, when they were low in vitamin and mineral contents. The decreased AST and ALT levels were probably due to a nutritional deficiency of pyridoxal phosphate which is a cofactor for both AST and ALT to catalyze the

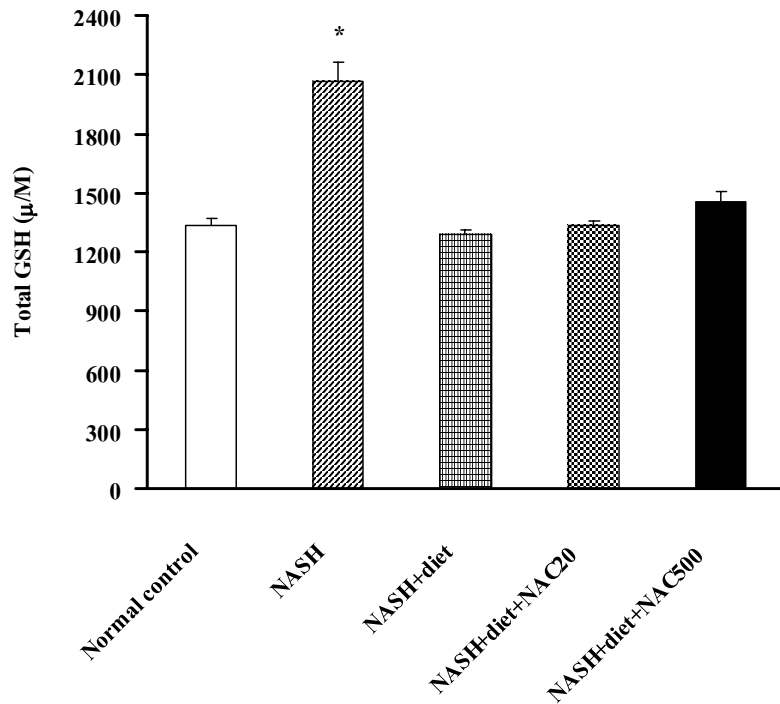


Fig. 1 Effect of NAC on total GSH level in rats with NASH (mean \pm SEM)
 * Significant difference ($p < 0.05$) compared with normal control group

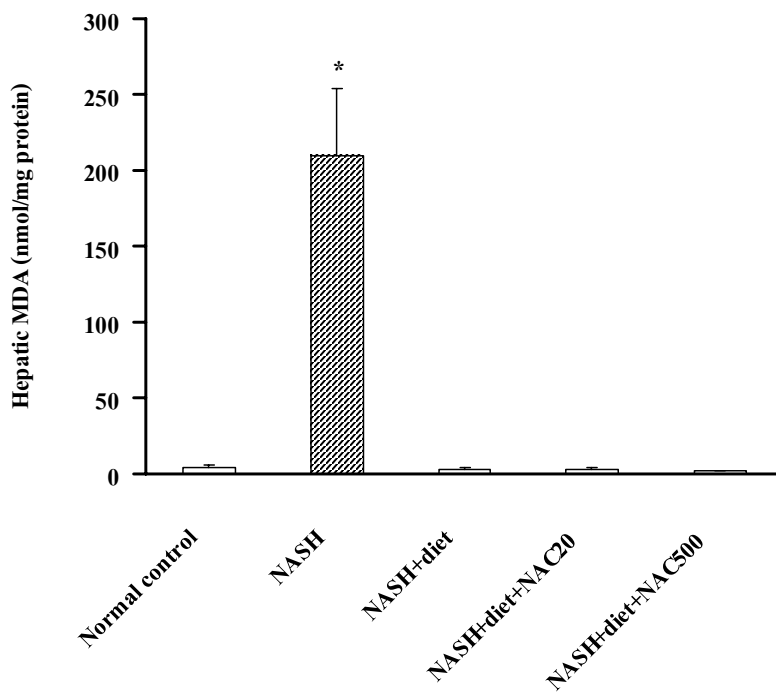


Fig. 2 Effect of NAC on hepatic MDA contents in rats with NASH (mean \pm SEM)
 * Significant difference ($p < 0.05$) compared with normal control group

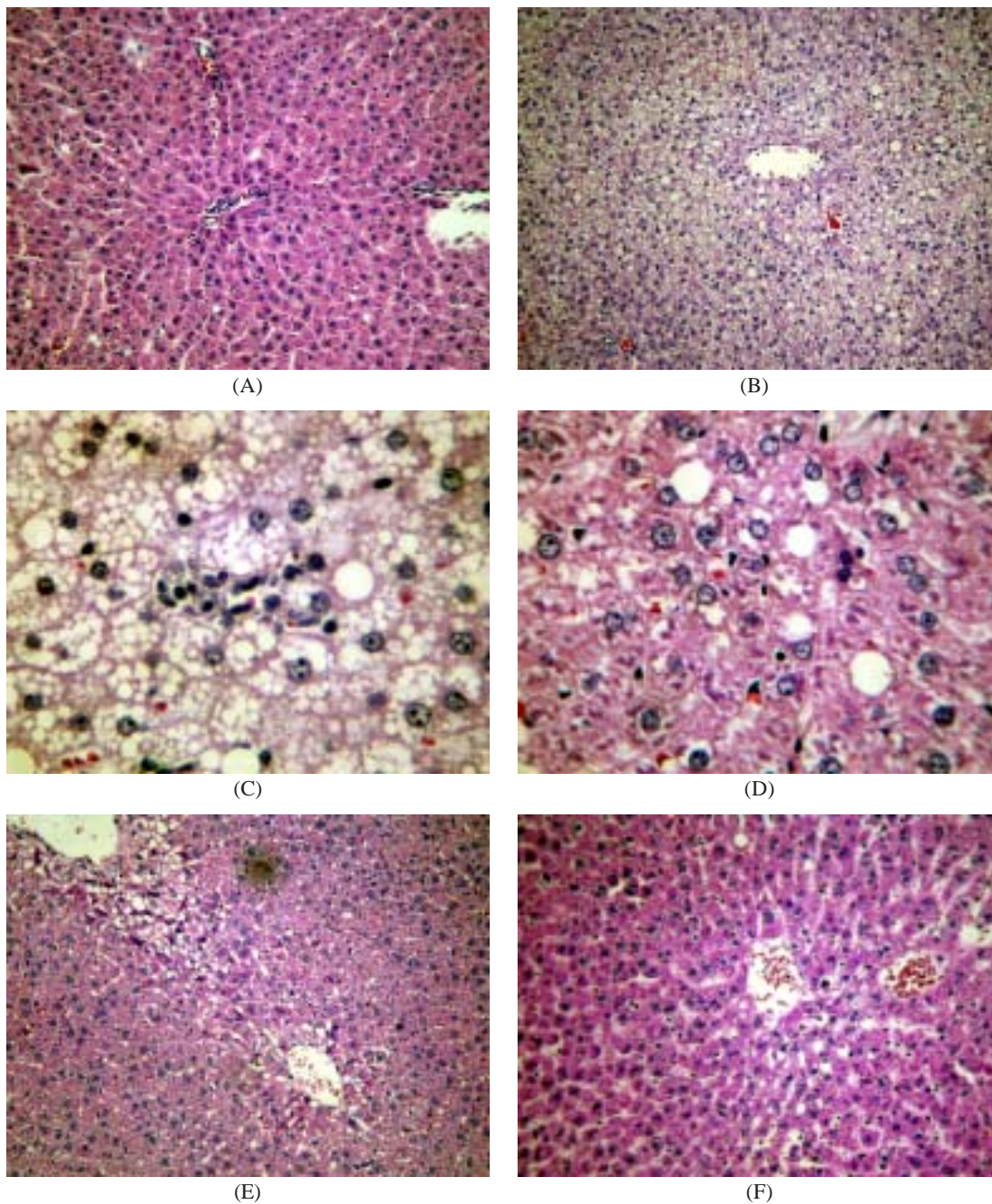


Fig. 3 Hematoxylin and eosin stain of liver sections in rats
 (A) normal control group
 (B,C) fed with 100% fat diet group showed macrovesicular steatosis, ballooning changes, Mallory bodies, hepatocyte necrosis, and infiltration of inflammatory cells
 (D) NASH rats + diet group showed an example of improvement in steatosis and necroinflammation; only mild steatosis and mild necroinflammation found in one rat
 (E) NASH rats + diet + NAC₂₀ group showed an example of improvement in steatosis and necroinflammation; only mild steatosis was found in three rats
 (F) NASH rats + diet + NAC₅₀₀ group showed no steatosis, no hepatocyte ballooning, and no inflammation (H&E, A, B, E, F = 100X, C, D = 400X)

transfer of the amino group from aspartate or alanine to a-ketoglutarate with made the release of pyruvate, oxaloacetate, and glutamate⁽²⁵⁾. In addition, oxidative stress condition may be a cause of hepatocyte death, therefore, aminotransferases cannot be produced.

FFA causes oxidative stress that has the potential to induce NASH⁽²⁾. FFA in the body is increased and this is associated with state of starvation⁽²⁾. Stored FFA can be mobilized from adipose tissue through lipolysis⁽²⁾. FFA metabolism increases the production of ROS that activates lipid peroxidation. The results are the disruption of membrane and the production of reactive metabolites such as MDA⁽²⁰⁾. The present study found high hepatic MDA in 100% fat - diet fed rats that agreed with the other experimental NASH rats^(24,27-29). In addition, an increasing in total glutathione in whole blood with 100% fat diet feeding could be explained by compensatory protection mechanism against oxidative stress.

In the diet treatment alone and diet plus NAC groups, total glutathione, serum AST, ALT, cholesterol, TG, and hepatic MDA returned to normal levels as in the control group. In addition, the pathological changes of liver in these groups were improved. These results emphasized how crucial the nutritional composition of the diet is. Good proportion of nutrients (i.e., carbohydrate, lipid, and protein) is essential for growth and maintenance. These nutrients supply energy, promote growth, repair body tissues, and regulate body processes⁽³¹⁾.

Conclusion

A resumed normal diet can attenuate oxidative stress, improve biochemical parameters and liver histopathology in rats with NASH. However, addition of NAC with diet is not better than control diet alone in the present study.

Some limitations of the present study deserve further discussion. First, the model in the present study represented malnutrition condition, but general patients with NASH were obese. In addition, this 100% fat diet is not supplemented with vitamin and mineral, and are possibly confounding factors causing no significant outcomes. However, both conditions provided the same pathological changes. Second, a previous study showed 100% fat induced-NASH in rats after 6 weeks and 12 weeks⁽³²⁾. The present study chose a 6-week duration because extreme weight loss found at 12 weeks may cause death of the animals. Third, in Cayman's GSH assay kit, sample preparation for measurement of GSSG (oxidized form) was generally

difficult. In the healthy cell, oxidized form rarely exceeds 10% of total glutathione (oxidized and reduced form), therefore the present study measured only total glutathione. Finally, there have been no studies of correlation between erythrocyte glutathione (total glutathione, GSH, and GSSG) and hepatic glutathione in rats with NASH. The present study found high total glutathione in whole blood (main source from erythrocytes) of rats with NASH. However, it was not able to infer hepatic glutathione.

Further studies should be conducted to explore the hypothesis that the decreased AST and ALT levels were probably due to deficiency of pyridoxal phosphate in rats with NASH. More studies should also examine both reduced and oxidized forms in erythrocytes and hepatic tissue.

Finally, within 6 weeks, 100% fat diet-induced macrovesicular steatosis, hepatocyte ballooning, and inflammation in rats was similar to histopathology of NASH. Treatment of NASH with diet or diet plus NAC could attenuate oxidative stress as well as improve biochemical parameters and liver histopathology. However, the result of additional NAC is not better than diet treatment alone. Further studies of NAC in NASH from other causes are necessary.

Acknowledgements

The present study had financial support from a grant of Graduated School and Grant of Ratchadapisek Somphok, Faculty of Medicine, Chulalongkorn University, Bangkok, Thailand.

References

1. Chalasani N, Deeg MA, Crabb DW. Systemic levels of lipid peroxidation and its metabolic and dietary correlates in patients with nonalcoholic steatohepatitis. *Am J Gastroenterol* 2004; 99: 1497-502.
2. Te SK, Bourass I, Sels JP, Driessen A, Stockbrugger RW, Koek GH. Non-alcoholic steatohepatitis: review of a growing medical problem. *Eur J Intern Med* 2004; 15: 10-21.
3. Medina J, Fernandez-Salazar LI, Garcia-Buey L, Moreno-Otero R. Approach to the pathogenesis and treatment of nonalcoholic steatohepatitis. *Diabetes Care* 2004; 27: 2057-66.
4. McCullough AJ. Update on nonalcoholic fatty liver disease. *J Clin Gastroenterol* 2002; 34: 255-62.
5. Lee RG. Nonalcoholic steatohepatitis: a study of 49 patients. *Hum Pathol* 1989; 20: 594-8.
6. Powell EE, Cooksley WG, Hanson R, Searle J, Halliday JW, Powell LW. The natural history of

- nonalcoholic steatohepatitis: a follow-up study of forty-two patients for up to 21 years. *Hepatology* 1990; 11: 74-80.
7. Bacon BR, Farahvash MJ, Janney CG, Neuschwander-Tetri BA. Nonalcoholic steatohepatitis: an expanded clinical entity. *Gastroenterology* 1994; 107: 1103-9.
 8. Garcia-Ruiz C, Colell A, Morales A, Kaplowitz N, Fernandez-Checa JC. Role of oxidative stress generated from the mitochondrial electron transport chain and mitochondrial glutathione status in loss of mitochondrial function and activation of transcription factor nuclear factor-kappa B: studies with isolated mitochondria and rat hepatocytes. *Mol Pharmacol* 1995; 48: 825-34.
 9. Weltman MD, Farrell GC, Liddle C. Increased hepatocyte CYP2E1 expression in a rat nutritional model of hepatic steatosis with inflammation. *Gastroenterology* 1996; 111: 1645-53.
 10. Robino G, Parola M, Marra F, Caligiuri A, De Franco RM, Zamara E, et al. Interaction between 4-hydroxy-2,3-alkenals and the platelet-derived growth factor-beta receptor. Reduced tyrosine phosphorylation and downstream signaling in hepatic stellate cells. *J Biol Chem* 2000; 275: 40561-7.
 11. Seki S, Kitada T, Yamada T, Sakaguchi H, Nakatani K, Wakasa K. In situ detection of lipid peroxidation and oxidative DNA damage in non-alcoholic fatty liver diseases. *J Hepatol* 2002; 37: 56-62.
 12. Capron JP, Delamarre J, Dupas JL, Braillon A, Degott C, Quenum C. Fasting in obesity: another cause of liver injury with alcoholic hyaline? *Dig Dis Sci* 1982; 27: 265-8.
 13. Gulbahar O, Karasu A, Ersoz G, Akarca US, Musoglu A. Treatment of non-alcoholic steatohepatitis with N-acetyl cysteine. *Gastroenterology* 2000; 118: A1444.
 14. Pastor A, Collado PS, Almar M, Gonzalez-Gallego J. Antioxidant enzyme status in biliary obstructed rats: effects of N-acetylcysteine. *J Hepatol* 1997; 27: 363-70.
 15. Pamuk GE, Sonsuz A. N-acetylcysteine in the treatment of non-alcoholic steatohepatitis. *J Gastroenterol Hepatol* 2003; 18: 1220-1.
 16. Ohkawa H, Ohishi N, Yagi K. Assay for lipid peroxides in animal tissues by thiobarbituric acid reaction. *Anal Biochem* 1979; 95: 351-8.
 17. Lowry OH, Rosebrough NJ, Farr AL, Randall RJ. Protein measurement with the Folin phenol reagent. *J Biol Chem* 1951; 193: 265-75.
 18. Brunt EM, Janney CG, Di Bisceglie AM, Neuschwander-Tetri BA, Bacon BR. Nonalcoholic steatohepatitis: a proposal for grading and staging the histological lesions. *Am J Gastroenterol* 1999; 94: 2467-74.
 19. Brody T. *Nutritional biochemistry*. 2nd ed. San Diego: Academic Press; 1994.
 20. Benzie IF. Lipid peroxidation: a review of causes, consequences, measurement and dietary influences. *Int J Food Sci Nutr* 1996; 47: 233-61.
 21. de Kneegt RJ. Non-alcoholic steatohepatitis: clinical significance and pathogenesis. *Scand J Gastroenterol* 2001; 36(Suppl 234): 88-92.
 22. Day CP. Pathogenesis of steatohepatitis. *Best Pract Res Clin Gastroenterol* 2002; 16: 663-78.
 23. Guyton AC, Hall JE. *Textbook of medical physiology*. 10th ed. Philadelphia: WB Saunders; 2000.
 24. Fan JG, Zhong L, Xu ZJ, Tia LY, Ding XD, Li MS, et al. Effects of low-calorie diet on steatohepatitis in rats with obesity and hyperlipidemia. *World J Gastroenterol* 2003; 9: 2045-9.
 25. Kaplowitz N. *Liver and biliary diseases*. Baltimore: Williams & Wilkins; 1992.
 26. Robbins SL. *Pathologic basic of disease*. London: W. B. Saunders; 1974.
 27. Leclercq IA, Farrell GC, Field J, Bell DR, Gonzalez FJ, Robertson GR. CYP2E1 and CYP4A as microsomal catalysts of lipid peroxides in murine nonalcoholic steatohepatitis. *J Clin Invest* 2000; 105: 1067-75.
 28. Kirsch R, Clarkson V, Shephard EG, Marais DA, Jaffer MA, Woodburne VE, et al. Rodent nutritional model of non-alcoholic steatohepatitis: species, strain and sex difference studies. *J Gastroenterol Hepatol* 2003; 18: 1272-82.
 29. George J, Pera N, Phung N, Leclercq I, Yun HJ, Farrell G. Lipid peroxidation, stellate cell activation and hepatic fibrogenesis in a rat model of chronic steatohepatitis. *J Hepatol* 2003; 39: 756-64.
 30. Kelly GS. Clinical applications of N-acetylcysteine. *Altern Med Rev* 1998; 3: 114-27.
 31. Guthrie HA. *Introductory nutrition*. 6th ed. St Louis: Mosby; 1986.
 32. Thong-Ngam D, Samuhasaneeto S, Suyasunanont D, Wisedopas N. Development of a simple rat model of nonalcoholic steatohepatitis. *Thai J Gastroenterol* 2005; 6: 144-8.

ผลของเอ็นอะซีทิลซีเอสทีอื่นต่อภาวะออกซิเดทีฟสเตรสในหนูขาวที่มีภาวะตับอักเสบจากไขมันลงตับ

สุจิตรา สมุหเสนีโต, ดวงพร ทองงาม, อรอนงค์ กุละพัฒน์, สุทธิลักษณ์ ปทุมราช, นฤมล คล้ายแก้ว

วัตถุประสงค์: เพื่อศึกษาผลของ เอ็นอะซีทิลซีเอสทีอื่น (NAC) ในการลดภาวะออกซิเดทีฟสเตรสในหนูขาวที่มีภาวะตับอักเสบจากไขมันลงตับ

วัสดุและวิธีการ: ทำการทดลองในหนูขาวเพศผู้ สายพันธุ์ Sprague-Dawley แบ่งโดยการสุ่มออกเป็น 5 กลุ่ม กลุ่มที่ 1 คือกลุ่มควบคุมปกติได้รับอาหารหนูเป็นเวลา 6 สัปดาห์ กลุ่มที่ 2 คือกลุ่มตับอักเสบจากไขมันลงตับซึ่งได้รับอาหารประกอบด้วยไขมันร้อยละ 100 เป็นเวลา 6 สัปดาห์ ส่วนกลุ่มที่ 3-5 คือกลุ่มที่ได้รับอาหารประกอบด้วยไขมันร้อยละ 100 เป็นเวลา 6 สัปดาห์ หลังจากนั้นเปลี่ยนมาให้อาหารหนูปกติ โดยกลุ่มที่ 3 เปลี่ยนอาหารเพียงอย่างเดียว (NASH + diet) กลุ่มที่ 4 เปลี่ยนอาหารและให้ NAC ขนาด 20 มิลลิกรัม/กิโลกรัม/วัน ทางปาก (NASH + diet + NAC₂₀) และกลุ่มที่ 5 เปลี่ยนอาหารและให้ NAC ขนาด 500 มิลลิกรัม/กิโลกรัม/วัน ทางปาก (NASH+diet+NAC₅₀₀) เป็นเวลาอีก 4 สัปดาห์ เมื่อสิ้นสุดการทดลองเก็บตัวอย่างเลือดและตับ

ผลการศึกษา: ระดับของกลูตาไทโอนและโคเลสเตอรอลในเลือด มาลอนไดอะดีไฮด์ในระดับสูงขึ้นอย่างมีนัยสำคัญในกลุ่มหนูตับอักเสบจากไขมันลงตับเปรียบเทียบกับกลุ่มควบคุมปกติ พยาธิสภาพของตับในกลุ่มที่ 2 มีปริมาณไขมันขนาดใหญ่ในไซโทพลาสซึมปานกลางถึงมาก เซลล์ตับวม มีการอักเสบและการตายของเซลล์ตับ การรักษาด้วยอาหาร หรือ อาหารร่วมกับ NAC สามารถลดระดับของกลูตาไทโอนและโคเลสเตอรอลในเลือด และมาลอนไดอะดีไฮด์ในระดับให้กลับคืนระดับปกติได้ และพยาธิสภาพของตับดีขึ้นโดยลดการสะสมไขมัน การตายและการอักเสบในเซลล์ตับ แต่ผลการให้อาหารหนูปกติร่วมกับ NAC ไม่ได้แตกต่างกับการให้อาหารหนูปกติเพียงอย่างเดียว

สรุป: การให้อาหารหนูปกติหรือการให้อาหารหนูปกติร่วมกับ NAC สามารถลดภาวะออกซิเดทีฟสเตรส และทำให้พยาธิสภาพของตับดีขึ้น และผลของการให้ NAC ร่วมด้วย ไม่ต่างจากการให้อาหารหนูปกติเพียงอย่างเดียว
