

Case Report

Carcinoid Tumor of the Middle Ear

Permsarp Isipradit MD*,
Saowaros Asawavichianginda MD*, Somboon Keelawat MD**

* Department of Otolaryngology, Faculty of Medicine, Chulalongkorn University

** Department of Pathology, Faculty of Medicine, Chulalongkorn University

The patient was a 32 year-old man who was first seen in 2003 for 2 years hearing loss. On otoscopic examination, a whitish mass could be observed through the intact tympanic membrane. High resolution computed tomography showed a tumor like lesion in the middle ear with no evidence of bone destruction. A tympanomastoidectomy was performed. Light microscopy showed fragments of cellular tissue in which both glandular and trabecular growth pattern could be identified. Immunohistochemical examinations showed positive staining of the tumor cells for cytokeratin and chromogranin. The diagnosis of carcinoid tumor should be considered in all cases of adenomatous neoplasms of the middle ear and mastoid. Conservative surgical excision is the treatment of choice, and local recurrence following complete excision is uncommon.

Keywords: Carcinoid tumor, Middle ear

J Med Assoc Thai 2007; 90 (4): 805-8

Full text. e-Journal: <http://www.medassocthai.org/journal>

The middle ear (ME) is a rare site for primary malignant tumors. The neoplasms most commonly encountered at this site in adults and children are squamous cell carcinoma and rhabdomyosarcoma, respectively. Primary tumors with glandular structures, such as ceruminoma, choristoma, monomorphic adenoma, and adenoid cystic carcinoma, are uncommon⁽¹⁻⁶⁾. A carcinoid tumor of the middle ear is a very rare neoplasm that represents a class within the spectrum of adenomatous neoplasms. Their true incidence is probably greater than reported because they are very difficult to distinguish from other middle ear adenomatous tumors by histopathology. A correct diagnosis that includes immunohistochemical studies and ultrastructural techniques (electron microscopy, EM) to show neurosecretory granules is important⁽¹⁻¹¹⁾.

The authors present a new case, together with a review of the literature.

Case Report

A 32 year old Thai male was first seen in January 2003 for hearing loss and fullness in his right ear that had persisted for 2 years. The medical and

familial histories were unremarkable. On otoscopic examination, a whitish mass could be seen through the intact tympanic membrane at the upper quadrant. An audiogram showed a conductive hearing loss on the right side; the air conduction threshold was 18 dB and the bone conduction threshold was 5 dB. Tympanometry revealed a flat type B trace on the right ear. High resolution computed tomography demonstrated a mass of soft tissue density in the ME with no evidence of temporal bone or ossicles destruction. The initial diagnosis was congenital cholesteatoma. The operative finding showed a reddish mass occupying the upper half of the mesotympanum, epitympanum with extension to the mastoid antrum. The mass encaged ossicles but there was no erosion. A tympanomastoidectomy was done and the tumor was removed together with the head of malleus and incus. Ossicular chain reconstruction was also performed.

Histologically, the neoplasm was characterized by diverse growth patterns of uniform tumor cells. These cells were arranged in small cellular clusters, large sheets, well-formed glands, or short strands (Fig. 1). Individual cells tended to be round, ovoid or cuboidal and contain a mildly hyperchromatic, round to ovoid and occasionally angulated nucleus without discernable nucleolus. Mitosis and necrosis were not seen. The background connective tissue around these tumor cells

Correspondence to : Isipradit P, Department of Otolaryngology, Faculty of Medicine, Chulalongkorn University, Bangkok 10330, Thailand. Phone: 0-2256-4103, Fax: 0-2252-7787, E-mail: iprmsarp@hotmail.com

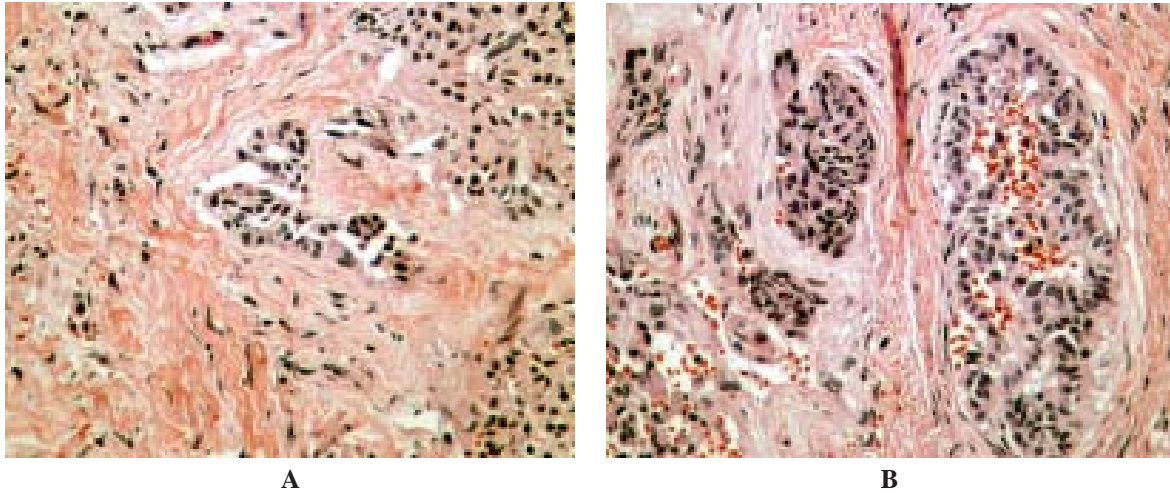


Fig. 1 Middle ear carcinoid composed of sheets, small clusters and glands of uniform epithelial cells (A, H&E *100), (B, H&E *400)

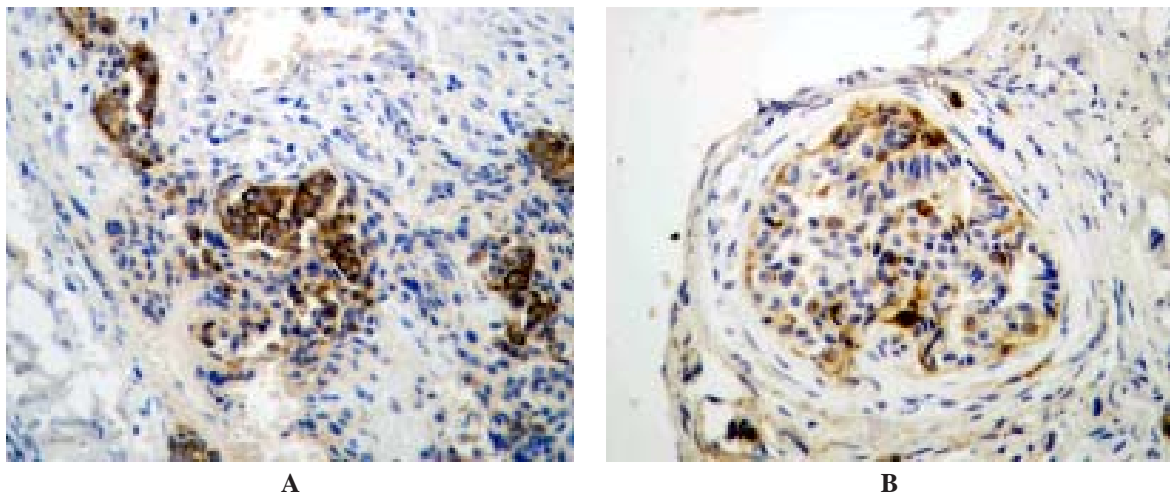


Fig. 2 Immunohistostaining, the tumor cells are strongly reactive to cytokeratin (A), and focally positive for chromogranin (B)

was infiltrated by many leukocytes, mainly plasma cells.

On immunohistochemical staining, the tumor cells were strongly reactive to cytokeratin (AE1/AE3) and focally positive for chromogranin (Fig. 2). However, they were negative for synaptophysin.

The post operative course was uncomplicated without signs of recurrence during one year follow up.

Discussion

The carcinoid tumor of the middle ear is very rare. The first publication by Murphy et al on carcinoid tumors of the middle ear appeared in 1980⁽¹⁾. An accurate review of the literature has shown that since 1980-

1999 only 37 cases of primary carcinoid tumor of the middle ear have been described⁽¹²⁾.

Although the diagnosis of carcinoid tumors is based on morphological findings, pathological confirmation of the diagnosis relies on immunohistochemical reactions and to a lesser degree on ultrastructural studies⁽¹⁻¹¹⁾. The tumors characteristics are 1) cellular arrangement is in solid trabecular or tubule glandular pattern 2) the presence of argyrophilic granules or immunoactivity for chromogranin/other neuroendocrine markers 3) the presence of neurosecretory granules detected by electron microscopy⁽¹⁻¹¹⁾. Murphy et al suggested that carcinoid tumors should be suspected

in cases of adenomatous lesions of the ME in which the histological appearance shows a trabecular growth pattern⁽¹⁾. The relationship between middle ear adenoma and carcinoid tumors is controversial. Most authors consider the tumors as two separate entities^(1,7-9) while others favor the view that they are closely related and are epithelial glandular neoplasm with varying degrees of neuroendocrine differentiation^(4-6,10,11).

The histogenesis of ME carcinoid tumors remains unclear, particularly because neuroendocrine cells have not been described in normal or inflamed ME mucosa^(13,14). Carcinoid tumors have been classified according to their sites of origin as foregut, midgut, or hindgut lesions. The mucosa of ME developed embryologically from the foregut (ME epithelium is endodermally derived as an extension of the first pharyngeal pouch) and endocrine cells are known to be present in the bronchopulmonary and upper gastrointestinal tracts, which are also derived from the foregut^(1,5-7,9-11). ME carcinoid tumors may originate from preexisting but undetected neuroendocrine cells. An alternative mechanism is the origin from a precursor epithelial stem cell (a primitive uncommitted cell of the lining epithelium of the ME) that is capable of differentiation into both endocrine and non-endocrine cells^(5,7,8).

Nearly all patients had progressive hearing loss, most often of conductive type. About half of the patients complained of tinnitus and aural fullness. The typical otoscopic pictures show erythema or lateral bulging of the tympanic membrane, which was intact in most cases. The tumor was most often localized to the middle ear with varying degree of extensions into neighboring areas. It often encapsulated the ossicles, which sometimes were eroded. In addition, foregut carcinoids generally produce only small amounts of peptide hormones, and therefore are usually systemically asymptomatic. Systemic symptoms were only reported in two cases^(4,6,8).

The tumor is clinically benign and total excision (tympanomastoidectomy or radical mastoidectomy) of the tumor and affected ossicles is an adequate treatment^(4-6,8,10).

Conclusion

The authors describe the first case of carcinoid tumor of the middle ear in Thailand. Carcinoid tumor of the middle ear is a very rare benign neoplasm, which may be mistaken for a malignant tumor. The correct diagnosis, which should be considered in case of adenomatous tumor of the middle ear, requires immu-

nohistochemical and ultrastructural procedures. The tumor is clinically benign, conservative surgery with radical removal of the tumor is the treatment of choice.

References

1. Lim DJ, Birck H. Ultrastructural pathology of the middle ear mucosa in serous otitis media. *Ann Otol Rhinol Laryngol* 1971; 80: 838-53.
2. Hentzer E. Ultrastructure of the middle ear mucosa. *Acta Otolaryngol Suppl* 1984; 414: 19-27.
3. Murphy GF, Pilch BZ, Dickersin GR, Goodman ML, Nadol JB Jr. Carcinoid tumor of the middle ear. *Am J Clin Pathol* 1980; 73: 816-23.
4. Krouse JH, Nadol JB Jr, Goodman ML. Carcinoid tumors of the middle ear. *Ann Otol Rhinol Laryngol* 1990; 99(7 Pt 1): 547-52.
5. Latif MA, Madders DJ, Barton RP, Shaw PA. Carcinoid tumour of the middle ear associated with systemic symptoms. *J Laryngol Otol* 1987; 101: 480-6.
6. Manni JJ, Faverly DR, Van Haelst UJ. Primary carcinoid tumors of the middle ear. Report on four cases and a review of the literature. *Arch Otolaryngol Head Neck Surg* 1992; 118: 1341-7.
7. Shibosawa E, Tsutsumi K, Ihara Y, Kinoshita H, Koizuka I. A case of carcinoid tumor of the middle ear. *Auris Nasus Larynx* 2003; 30(Suppl): S99-102.
8. Nyrop M, Guldhammer SB, Katholm M, Nielsen HW. Carcinoid tumor of the middle ear. *Ear Nose Throat J* 1994; 73: 688-93.
9. Devaney KO, Ferlito A, Rinaldo A. Epithelial tumors of the middle ear - are middle ear carcinoids really distinct from middle ear adenomas? *Acta Otolaryngol* 2003; 123: 678-82.
10. Kodama H, Takezawa H, Suzuki T, Kobayashi K, Kataura A, Wakabayashi J, et al. Carcinoid tumour of the middle ear. *J Laryngol Otol* 1989; 103: 86-91.
11. Tange RA, vd Borden J, Schipper ME, Mooi WM. A case of carcinoid tumor of the middle ear. *J Laryngol Otol* 1984; 98: 1021-6.
12. Davies JE, Semeraro D, Knight LC, Griffiths GJ. Middle ear neoplasms showing adenomatous and neuroendocrine components. *J Laryngol Otol* 1989; 103: 404-7.
13. Friedmann I, Galey FR, House WF, Carberry JN, Ward PP. A mixed carcinoid tumour of the middle ear. *J Laryngol Otol* 1983; 97: 465-70.
14. Ferri E, Cavaleri S, Ianniello F, Longo L. Primitive carcinoid tumor of the middle ear: a case report and review of literature. *Acta Otorhinolaryngol Ital* 1999; 19: 91-6.

เนื้องอกชนิดคาร์ซินอยด์ของหูชั้นกลาง

เพิ่มทรัพย์ อธิประดิษฐ์, เสาวรส อัครวิเชียรจินดา, สมบูรณ์ ศีลาวัฒน์

ชายไทยอายุ 32 ปี มาตรวจเมื่อ พ.ศ. 2546 ด้วยอาการการได้ยินลดลงเป็นเวลา 2 ปี ตรวจร่างกายพบก้อนเนื้อสีขาวอยู่หลังเยื่อแก้วหูที่มีลักษณะปกติ การตรวจทางรังสีคอมพิวเตอร์พบก้อนเนื้ออกในหูชั้นกลางแต่ไม่มีลักษณะการทำลายของกระดูกบริเวณข้างเคียง ได้ทำการผ่าตัดเอาก้อนออกด้วยวิธี tympanomastoidectomy การตรวจชิ้นเนื้อทางพยาธิวิทยา พบว่าเซลล์มีการเรียงตัวแบบ glandular และ trabecular การย้อมพิเศษให้ผลบวกกับ cytokeratin และ chromogranin จึงให้การวินิจฉัยว่าเป็นเนื้องอกชนิดคาร์ซินอยด์ ซึ่งเป็นชนิดที่ควรนึกถึงเสมอในรายที่เป็นเนื้องอกชนิด adenoma ของหูชั้นกลางและกระดูกมาสเตอร์ การรักษาโดยวิธีการผ่าตัดเป็นวิธีการรักษาหลัก โอกาสเกิดขึ้นใหม่หลัง การผ่าตัดพบได้น้อยมาก
