

Sensitivity of Mammography and Ultrasonography on Detecting Abnormal Findings of Ductal Carcinoma *in Situ*

Darunee Boonjunwetwat MD*, Uraiwan Chyutipraiwan MD*,
Pichet Sampatanukul MD, MSc**, Kris Chatamra MD***

* Departments of Radiology, Faculty of Medicine, Chulalongkorn University

** Departments of Pathology, Faculty of Medicine, Chulalongkorn University

*** Departments of Surgery, Faculty of Medicine, Chulalongkorn University

Objective: To analyze the mammographic and ultrasonographic findings of ductal carcinoma in situ (DCIS) and determine the sensitivity in Thai women.

Material and Method: Mammograms and bilateral whole-breast ultrasonograms of 37 proven cases of DCIS were reviewed. The former was assessed for microcalcifications and soft tissue densities while the latter was evaluated for masses and thickened ducts. Ultrasonography was used to spot the areas to visualize soft tissue densities in mammogram.

Results: Mammography detected 22 cases of DCIS having pure microcalcifications, eight cases with mixed microcalcifications and soft tissue densities, six cases with pure abnormal soft tissue densities and one case showing negative finding. The ultrasonography detected 13 cases showing masses, seven cases as showing thickened ducts and 17 cases as negative findings.

Conclusion: Microcalcifications are characteristic findings in mammogram accounting for 81% of DCIS in the present study. Ultrasonography shows abnormalities including mass and thickened duct lesions in 54% of DCIS. The combined modalities can give the detection of abnormalities in 97% of DCIS.

Keywords: Mammography, Ultrasonography, Breast, Ductal carcinoma in situ

J Med Assoc Thai 2007; 90 (3): 539-45

Full text. e-Journal: <http://www.medassocthai.org/journal>

Ductal carcinoma *in situ* (DCIS) is a primary malignant neoplasm of the breast that is confined to the ducts without invasion into the breast stroma. Thus when breast cancer patients are treated at this stage, usually discovered on screening mammography, it results in cure or a high survival rate. The ability of mammography to depict and diagnose this non-invasive cancer is well accepted, on the basis of presence of characteristic calcifications⁽¹⁻⁵⁾. However, a number of DCIS appear as soft tissue abnormalities without calcifications⁽³⁾. The latter might be the source of miss with detection by mammography alone. Additionally,

the sensitivity of mammography declines significantly with increasing breast density^(6,7). Ultrasonography (US) becomes accepted in that it can depict occult cancers at a size and stage similar to those detected by mammography⁽⁶⁻⁹⁾. In Thailand, many institutes including the Department of Radiology, Faculty of Medicine, Chulalongkorn University have performed ultrasonography complementary to mammography as routine service since Thai women mostly have a dense breast pattern. To determine the sensitivity, the authors analyzed the mammographic and ultrasonographic features of 37 biopsy-proved DCIS.

Correspondence to : Sampatanukul P, Department of Pathology, Faculty of Medicine, Chulalongkorn University, Bangkok 10330, Thailand. Phone: 081-926-9324, Fax: 0-2652-4208, E-mail: fmedpst@md2.md.chula.ac.th

Material and Method

From January 1996 to April 2006, 37 histology-proved DCIS patients who had both mammographic

and ultrasonographic studies were reviewed by one of the authors (DB). All of the cases had been collected from the weekly Breast Conference of the Queen Sirikit Breast Center, King Chulalongkorn Memorial Hospital. On the review, mammograms were analyzed for microcalcifications and stromal densities while ultrasonograms were evaluated for mass lesions and thickened ducts. A mass lesion was defined as a hypoechoic area or nodule whereas a thickened duct was defined as a regional widening of tubular or branching hypoechoic structure.

Bilateral mammography was performed using full-field digital mammography of Lorad Selenia. Two views were routinely employed - craniocaudal and mediolateral oblique views. When any suspect was seen, spot or magnification, views over the area were further done.

Bilateral whole-breast ultrasonography was performed with high-resolution transducers. Two machines were available - the Phillips iu22 and the GE Voluson 730 Expert. The ultrasonography was done immediately following the mammography. It not only gave complementary findings but also guided localization for spot or magnification view of mammography.

Ductography was performed in one case that presented with nipple discharge. Both mammography and ultrasonography showed negative findings.

Results

The ages of the 37 patients ranged from 24 to 73 years (mean, 49.6 years). The lesions were found in the left breast more than in the right side and the most common site of the lesions was upper outer

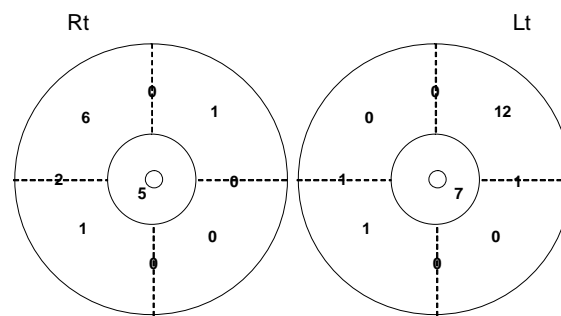


Diagram 1. Frequency distribution of sites of the DCIS lesions

quadrant (Diagram 1). The size of the lesions were divided into three groups namely subcentimeter size group (12 cases), 1-2 cm size group (12 cases) and > 2 cm size group (13 cases).

Mammographic findings

Mammograms showed abnormalities in 36 cases. The frequency distribution of the abnormalities has been illustrated together with two other centers for comparison (Table 1).

The microcalcifications were classified as linear (Fig. 1A), granular (Fig. 1B) and mixed forms (Fig. 1C). The most common type was granular pattern. The comparison of the frequency of type of microcalcifications is demonstrated (Table 2).

There were 16 soft tissue abnormalities in 14 patients. They consisted of three mass lesions (Fig. 2A), 10 asymmetric densities (Fig. 2B) and three architectural distortions (Fig. 2C). Two patients with double

Table 1. Comparison of mammographic findings of DCIS among three institutions

Findings	King Chula. Memo. Hosp. (2006)	Stomper et al (1989) ⁽⁴⁾	Wazer et al (1996) ⁽⁵⁾
Abnormal MC	22 (59.5%)	72%	83.8%
Abnormal MC + ST	8 (21.6%)	12%	13.5%
Abnormal ST	6 (16.2%)	10%	2.7%
Negative	1* (2.7%)	6%**	
Total	37 lesions		
Total abnormal MC = 22 + 8 = 30 lesions = 81%		84%	97.3%
Total abnormal ST = 8 + 6 = 14 lesions = 54%		22%	16.2%

* Positive ductogram

** Incidental findings in biopsy specimens

MC = microcalcifications

ST = soft tissue abnormalities

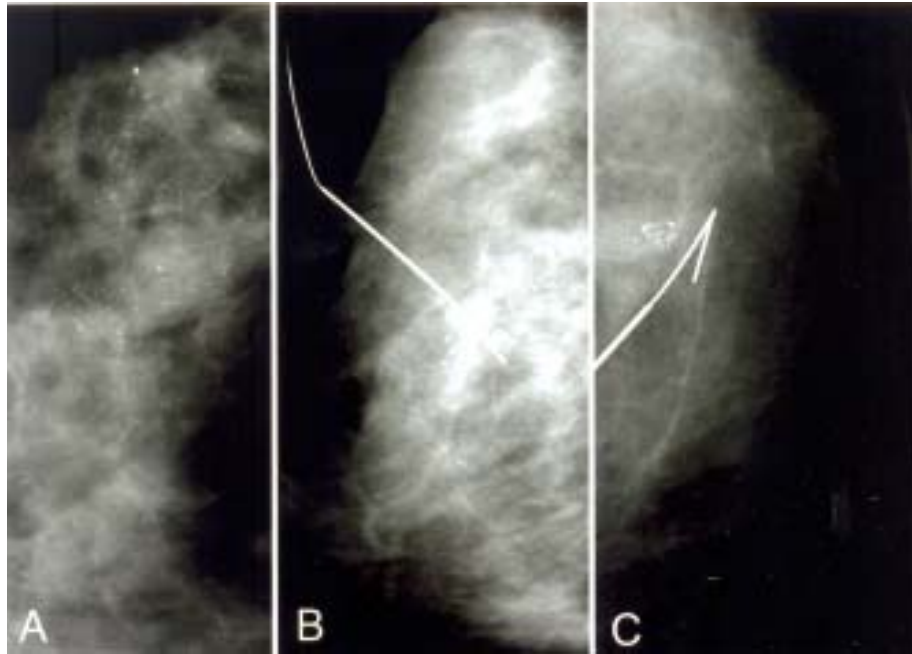


Fig. 1 Mammographic findings of microcalcifications in DCIS cases
 A: linear
 B: granular
 C: mixed forms

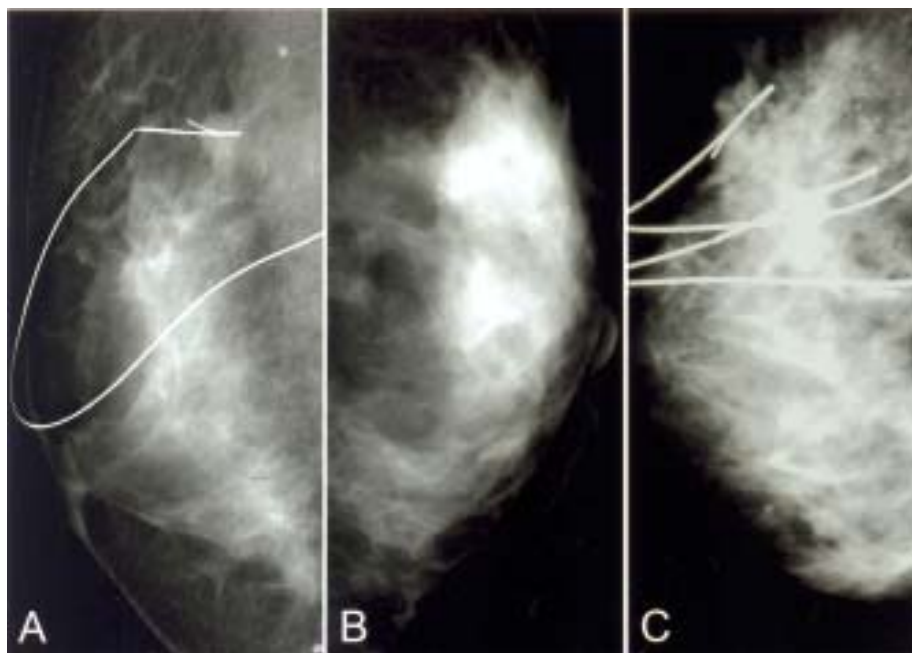


Fig. 2 Mammographic findings of abnormal soft tissue densities in DCIS cases
 A: mass lesion
 B: asymmetric density
 C: architectural distortion

Table 2. Comparison of frequency of types of microcalcifications

Types of microcalcifications	King Chula. Memo. Hosp. (2006)	Stomper et al (2000) ⁽¹⁾
Linear	8 (26.7%)	47 (32.4%)
Granular	12 (40.0%)	62 (42.8%)
Mixed	10 (33.3%)	36 (24.8%)
Total	30	145

findings were one case having mass with asymmetric density and the other having mass with architectural distortion.

Ultrasonographic findings

Ultrasonograms revealed the indicated lesions in 20 cases. There were 13 mass lesions (Fig. 3A, B) and seven thickened ducts (Fig. 3C, D). Of these, calcifications were visualized in five patients. The calcifications were found within soft tissue masses in four patients and within the thickened duct in one case.

Combination of mammographic and ultrasonographic findings

The combination is shown in Table 3. Nine out of 13 ultrasonographic soft tissue masses had positive microcalcifications on mammograms. Ultrasonogram depicted microcalcifications in four. Each of the three visualized cases had the mass lesion larger than 1 cm whereas each of the four non-visualized lesions revealed subcentimeter in size. On the other hand, mammography was able to demonstrate abnormal soft tissue densities in 11 cases out of the 13 cases.

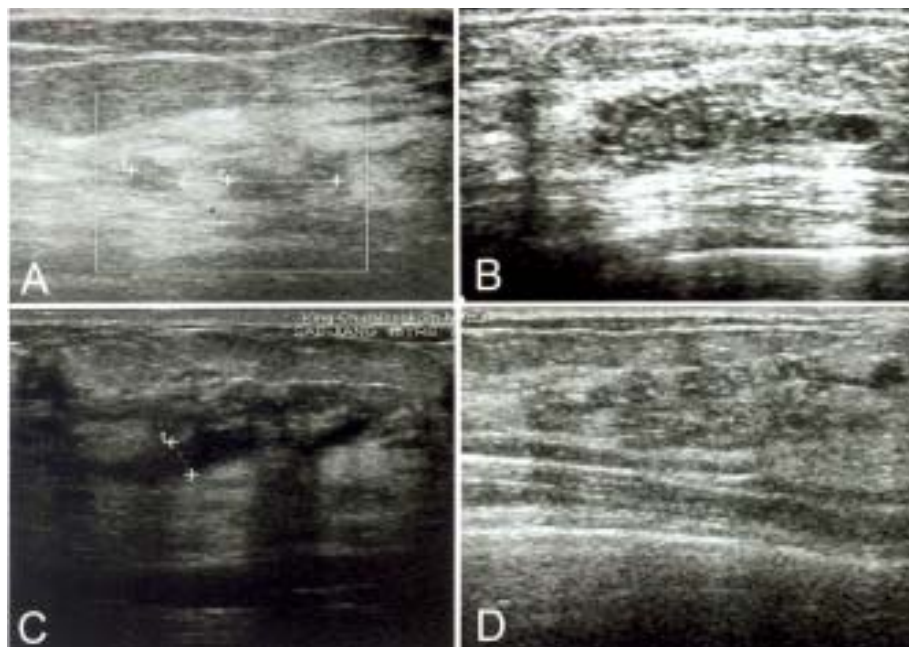


Fig. 3 Ultrasonographic findings in DCIS cases
A: mass lesion
B: mass lesion with visible microcalcifications
C: thickened duct
D: thickened duct with visible microcalcifications

Table 3. Combined ultrasonographic and mammographic findings

US findings		Mammographic findings		
		ST	ST + MC	MC
Mass w MC	4	0	3	1
Mass w/o MC	9	4	4	1
Thickened duct w MC	1	0	0	1
Thickened duct w/o MC	6	2	1	3
Negative	17	0	0	16*
Total	37	6	8	22

* One case with negative mammogram, but positive ductogram

ST = soft tissue abnormalities

MC = microcalcifications

w = with

w/o = without

Five out of seven ultrasonographic with thickened duct lesions had positive microcalcifications on mammograms. Ultrasonogram can depict microcalcification in only one case. It had the greatest dimension of more than 2 cm. On contrary, mammography can display abnormal soft tissue densities in three cases of these seven cases.

Of the 17 negative cases by ultrasonogram, 16 had mammographic microcalcifications and one case had negative mammogram but positive ductogram.

In overall, ultrasonography showed abnormalities including mass and thickened duct lesions in 20/37 = 54% of DCIS. The efficacy on microcalcifications detection was 5/30 = 16.7%. Microcalcifications were the characteristic finding in mammograms accounting for 30/37 = 81% of DCIS. The detection rate for abnormal densities was 14/20 = 70%. Finally, the combined modalities gave the detection of abnormalities in 36/37 = 97% of DCIS.

Discussion

Dense breasts, which include the ACR BI-RADS heterogeneously dense and extremely dense categories, are frequently found among Thai women. The authors' study (unpublished data) shows dense breast pattern accounting for 91% of females aged 35-44, 86.4% of females aged 45-54, 72.7% of females aged 55-64 and 37.4% of females aged 65-74. Accordingly, the patients of DCIS in the present study had a mean age of 49.6 years and mostly dense breast pattern. The

mammographic sensitivity for the present study is therefore less than for the studies from Western countries (Table 1). There is a need for supplementary ultrasonography to enhance the detection rate.

Ductal carcinoma *in situ* (DCIS) is a proliferation of morphologically malignant epithelial cells confined to the mammary ducts and lobules with no evidence of invasion through the basement membrane into the surrounding stroma⁽¹⁾. This is a heterogeneous disease with a wide range of sizes and different pathological, mammographic, and biological characteristics. In the present study, one third had subcentimetered lesions, one third were the size of 1-2 cm and the other one third were of a size larger than 2 cm. DCIS showing microcalcifications accounts for 81%. DCIS with soft tissue abnormality accounts for 54%. DCIS showing mixed microcalcifications and abnormal soft tissue density comprises 21.6% of the total.

The mammographic features of DCIS have been well described in literatures, with microcalcifications being the dominant findings of about 60-97%^(1-5,10,11) and the granular type is slightly commoner than the linear type and mixed type as in the present study and others^(1,2,12). The incidence of microcalcifications in DCIS is higher in asymptomatic⁽²⁾ and younger patients⁽¹⁾. Mammographic sensitivity is significantly inversely related to breast density, decreases from 100% in fatty breasts to 45-48% in extremely dense breasts^(6,7). Detection of DCIS using mammography alone may be suboptimal especially among Thai women.

The complement of screening bilateral whole-breast ultrasonography significantly increases detection of small breast cancers^(6,7,9). Mammography and ultrasonography together had much higher sensitivity (97%) than did mammography and physical examinations together (74%) and depicting significantly more cancers and at smaller size and lower stage⁽⁶⁾. The capability of high-resolution ultrasonography in detecting microcalcifications of breast cancer is reported, especially when they are within a mass lesion or clusters larger than 1 cm as the present study and others^(8,13-15). The usage and the features of ultrasonography in detecting DCIS have been described in other studies as well^(15,16).

In the present study, additional ultrasonography is more sensitive in detection of the soft tissue abnormalities than mammography. The latter can detect only 70% of abnormal soft tissue in 20 cases of ultrasonographically detected lesions. Indeed, most of the abnormal soft tissue densities seen on mammograms in the present study are detected on spot compression views guided by ultrasonograms. This should be the reason of high percentage of abnormal soft tissue density on mammography in the present study compared to previous reports^(4,5). Ultrasonography is relatively capable of depicting clustered microcalcifications associated with masses larger than 1 cm with given known mammographic location⁽⁸⁾. However, it is difficult to visualize microcalcifications inside small masses or thickened duct lesions, particularly those less than 0.5 cm⁽¹⁶⁾.

In summary, mammography is superior to ultrasonography on detection of microcalcifications that accounts for 81% of the DCIS cases. Ultrasonography reveals masses and thickened ducts with or without visible calcifications and totally account for 54%. On the other hand, with the support of ultrasonography, the mammograms can depict the soft tissue abnormalities in 70% of the cases. The combined modalities can give the detection of abnormalities in 97% of DCIS.

References

1. Stomper PC, Winston JS, Proulx GM, Hurd TC, Edge SB. Mammographic detection and staging of ductal carcinoma in situ: mammographic-pathological correlation. *Semin Breast Dis* 2000; 3: 26-41.
2. Evans AJ, Pinder S, Ellis IO, Sibbering M, Elston CW, Poller DN, et al. Screening-detected and symptomatic ductal carcinoma in situ: mammographic features with pathologic correlation. *Radiology* 1994; 191: 237-40.
3. Ikeda DM, Andersson I. Ductal carcinoma in situ: atypical mammographic appearances. *Radiology* 1989; 172: 661-6.
4. Stomper PC, Connolly JL, Meyer JE, Harris JR. Clinically occult ductal carcinoma in situ detected with mammography: analysis of 100 cases with radiologic-pathologic correlation. *Radiology* 1989; 172: 235-41.
5. Wazer DE, Gage I, Homer MJ, Krosnick SH, Schmid C. Age-related differences in patients with nonpalpable breast carcinomas. *Cancer* 1996; 78: 1432-7.
6. Kolb TM, Lichy J, Newhouse JH. Comparison of the performance of screening mammography, physical examination, and breast US and evaluation of factors that influence them: an analysis of 27,825 patient evaluations. *Radiology* 2002; 225: 165-75.
7. Berg WA, Gutierrez L, NessAiver MS, Carter WB, Bhargavan M, Lewis RS, et al. Diagnostic accuracy of mammography, clinical examination, US, and MR imaging in preoperative assessment of breast cancer. *Radiology* 2004; 233: 830-49.
8. Moon WK, Im JG, Koh YH, Noh DY, Park IA. US of mammographically detected clustered microcalcifications. *Radiology* 2000; 217: 849-54.
9. Kaplan SS. Clinical utility of bilateral whole-breast US in the evaluation of women with dense breast tissue. *Radiology* 2001; 221: 641-9.
10. Dershaw DD, Abramson A, Kinne DW. Ductal carcinoma in situ: mammographic findings and clinical implications. *Radiology* 1989; 170: 411-5.
11. Holland R, Hendriks JH. Microcalcifications associated with ductal carcinoma in situ: mammographic-pathologic correlation. *Semin Diagn Pathol* 1994; 11: 181-92.
12. Stomper PC, Margolin FR. Ductal carcinoma in situ: the mammographer's perspective. *AJR Am J Roentgenol* 1994; 162: 585-91.
13. Yang WT, Suen M, Ahuja A, Metreweli C. In vivo demonstration of microcalcification in breast cancer using high resolution ultrasound. *Br J Radiol* 1997; 70: 685-90.
14. Gufler H, Buitrago-Tellez CH, Madjar H, Allmann KH, Uhl M, Rohr-Reyes A. Ultrasound demonstration of mammographically detected microcalcifications. *Acta Radiol* 2000; 41: 217-21.
15. Yang WT, Tse GM. Sonographic, mammographic, and histopathologic correlation of symptomatic ductal carcinoma in situ. *AJR Am J Roentgenol*

ความไวของแมมโมแกรมและอัลตราซาวด์ในการตรวจพบรอยโรคของมะเร็งเต้านมระยะไม่ลุกลาม

ดรณี บุญยืนเวทวัฒน์, อุไรวรรณ ชยดีไพรวลัย, พิเชฐ สัมปทานุกุล, กฤษณ์ จาฎามระ

วัตถุประสงค์: เพื่อวิเคราะห์ลักษณะทางภาพแมมโมแกรมและอัลตราซาวด์ของมะเร็งเต้านมระยะไม่ลุกลามและความไวของแมมโมแกรมในสตรีไทย

วัสดุและวิธีการ: ศึกษาภาพบันทึกแมมโมแกรมและอัลตราซาวด์ของผู้ป่วยที่มีผลทางพยาธิวิทยายืนยันว่าเป็นมะเร็งเต้านมระยะไม่ลุกลามจำนวน 37 คน ภาพบันทึกแมมโมแกรมวิเคราะห์หา microcalcification และ soft tissue density ขณะที่ภาพอัลตราซาวด์ตรวจหารอยโรคก้อนและลักษณะของท่อที่ดูหนาขึ้น การศึกษานี้อัลตราซาวด์ได้ถูกใช้ในการระบุตำแหน่งที่จะบันทึกแมมโมแกรมขยายให้เห็นลักษณะของ abnormal soft tissue density

ผลการศึกษา: แมมโมแกรมตรวจพบ microcalcification อย่างเดียวในผู้ป่วยจำนวน 22 คน พบ microcalcification ร่วมกับ soft tissue density ในผู้ป่วย 8 คน พบเป็น abnormal soft tissue density อย่างเดียวจำนวน 6 คน และไม่พบความผิดปกติ 1 คน ขณะที่อัลตราซาวด์พบผู้ป่วย 13 คนมีลักษณะของก้อน ผู้ป่วย 7 คนมีลักษณะของท่อที่ดูหนาขึ้น และผู้ป่วยอีก 17 คนไม่พบลักษณะผิดปกติ

สรุป: ผู้ป่วยมะเร็งเต้านมระยะไม่ลุกลามพบ microcalcification ซึ่งเป็นลักษณะจำเพาะโดยแมมโมแกรม ร้อยละ 81 พบลักษณะของก้อนและท่อหนาตัวโดยอัลตราซาวด์ ร้อยละ 54 เมื่อรวมทั้งสองวิธีเข้าด้วยกัน จะสามารถตรวจพบความผิดปกติร้อยละ 97 ของผู้ป่วย
