

Case Report

Hand-Assisted Laparoscopic Partial Nephrectomy for Renal Cell Carcinoma: The First Case Report in Thailand: Case Report

Kittinut Kijvikai MD*,
Apichai Tongdornbom MD*, Wachira Kochakarn MD*

* Division of Urology, Department of Surgery, Faculty of Medicine, Ramathibodi Hospital, Mahidol University

The authors report their first experience on a hand-assisted laparoscopic partial nephrectomy surgical technique and the result after it was performed successfully in a 45-year-old woman who presented with an asymptomatic small renal mass. This is the first successful case report of this operation in Thailand.

Keywords: Hand-assisted laparoscopy, Renal cell carcinoma, Partial nephrectomy

J Med Assoc Thai 2006; 89 (10): 1749-52

Full text. e-Journal: <http://www.medassocthai.org/journal>

Partial nephrectomy has been a gold standard in the management of small renal masses⁽¹⁾. In the 1990s, several successful initial laparoscopic partial nephrectomy (LPN) series were reported and the major complication of LPN was significant renal hemorrhage⁽²⁻⁷⁾. Many techniques such as hydro-jet dissection, high frequency bipolar electrical current, ultrasound, microwave, electro-surgical snare electrode, and radio-frequency coagulation assistance have been described with the objective of decreasing operative blood loss^(2,8-13). Hand-assisted laparoscopic partial nephrectomy (HALPN) has also been described⁽¹⁴⁻¹⁶⁾.

In the present report, the authors described the HALPN technique and the result of the successful surgery for renal cell carcinoma. This is the first case report in Thailand.

Case Report

A 45-year-old woman weighing 60 Kg was presented with asymptomatic microscopic hematuria. Ultrasonography showed a solid right renal mass. Computed tomography confirmed 3.5 cm solid enhancing renal mass at the peripheral middle pole of the right

kidney. The left kidney was within normal limit. With a high suspicion of cancer and after having the therapeutic options explained, the patient gave her consent to undergo HALPN.

Technique

The patient was placed in 45 degree with the right side up and flexion position. A 7-cm right lower quadrant incision (Fig. 1) was made and a hand port device (Lap Disc) was placed. The peritoneum was insufflated and three 10 mm ports were placed at umbilicus, midline between epigastrium and umbilicus and midclavicular line below right costal margin (Fig. 1). The colon was mobilized and Gerota's fascia was entered laterally. The perinephric fat was cleared except for that overlying the tumor and the examined kidney. The duodenum was mobilized, the renal hilum was dissected, and the renal artery was temporarily clamped with a bulldog vascular clamp. Mannitol was given approximately 30 minutes before vascular clamping. The renal vein was surrounded by a vascular loop without occlusion. Then, the kidney was cooled with ice slush through the hand port device. After 10 minutes of waiting to achieve protective hypothermic temperatures (15C), the renal capsule was scored 5 mm from the tumor and an endoscope scissor without cautery was used for tumor resection. Hemostasis was achieved with 3-0 absorbable sutures, followed by placement of

Correspondence to : Kijvikai K, Division of Urology, Department of Surgery, Faculty of Medicine, Ramathibodi Hospital, Mahidol University, 270 Rama 6 Rd, Tungphayatai, Rajathevee, Bangkok 10400, Thailand. Phone: 0-2201-1315, Fax: 0-2201-1316, E-mail: kittinutk@hotmail.com

perinephric fat and bandage of surgical. The renal parenchyma defect was closed with 2-0 absorbable intracorporeal laparoscopic sutures. The vascular clamp was removed and bleeding point was stopped. Gerota's fascia was reapproximated around the kidney and a closed suction drain was left in the retroperitoneum.

Total operative time was 250 minutes and the cold ischemic time was 55 minutes. The operative blood loss was 350 ml. Only 8 mg of morphine was used for pain relief. The drain was removed on the postoperative day 4 and the patient was discharged from the hospital on the fifth postoperative day.

Histopathology revealed renal cell carcinoma with free surgical margin. Postoperation was uneventful except prolonged ileus. The clinical conditions were improved within 1 week after supportive treatment. The patient was doing well thereafter.

Discussion

Currently, the advance of laparoscopic surgery has led to changes in the management of renal masses. The controversy involves whether standard LPN or HALPN laparoscopic intervention should be used in renal surgery^(17,18). In 1993, Winfield and colleagues⁽³⁾ reported the first successful LPN. Since then there have been fewer than 100 cases published in the world literature. This limited acceptance is likely due to multiple factors. LPN requires an experienced laparoscopic surgeon and bleeding may be more difficult to control in the standard laparoscopic environment⁽¹⁹⁾. In addition, the kidney is not cool when the pedicle is clamped, and there is no hand for compression in the

operative field⁽¹⁹⁾. Several authors have reported that the HALPN has proved to be feasible and reproducible^(14-16,19). Potential advantages include the ability to perform complex deep resections, repair the collecting system with sutures, manipulate the kidney orientation for superior resection angles, and immediately extract and confirm margin status. Moreover, hypothermia provides an unhurried resection, delicate margin assessment, and longer period of reconstruction⁽²⁰⁾. While the devices for standard LPN such as radio frequency dissection device have proven capable of deep parenchymal resection and hemostasis without the need for temporary vascular clamping or renal hypothermia, there are several potential pitfalls including the potential for difficulty with choosing the proper plane of resection to completely remove the lesion, collecting system leakage often requiring drainage, and the extremely time-consuming technique required for deeper lesions⁽²⁰⁾. Moreover, the authors believed that these high cost devices are not suitable for Thailand where most of the patients have socio-economic problems.

Brown et al⁽²¹⁾ have suggested that closure of small urothelial disruptions during partial nephrectomy for peripheral tumors may be less important than that of central tumor. Therefore, the authors did not confirm collecting system integrity by using dye after having completed the operation.

HALPN is as effective as standard laparoscopy in terms of decreasing hospital stay, narcotic requirement and quickening convalescence⁽²²⁾. However, as with all hand assisted approaches the disadvantages include the need for a 7 to 8 cm incision, often for removal of a 3 to 4 cm lesion⁽²⁰⁾.

Although this management was the first experience in our institute, the operative blood loss and the operation time were comparable with one of the largest series report⁽²¹⁾. These may infer that HALPN needs less steep learning curve and can be performed by a less experienced laparoscopic surgeon. The narcotic requirement and postoperative convalescence were similar to those of other series^(19,21). The authors had no transfusions or major complications. However, the patient had persistent ileus necessitating readmission for intravenous fluid for one week, but was doing well thereafter.

Conclusion

HALPN is feasible, safe, and reproducible. The benefits of HALPN are the ability of the surgeon's hand to facilitate dissection, vascular control, hemo-

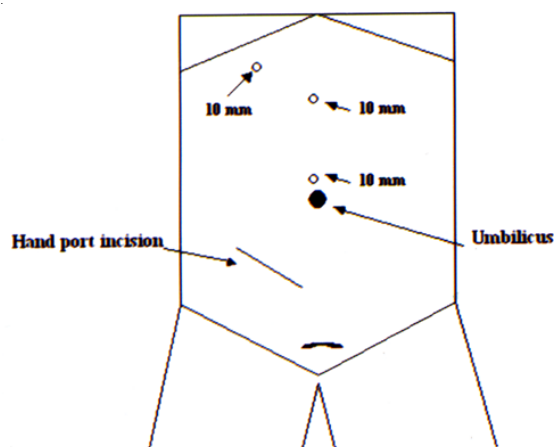


Fig. 1 A picture shows incision for hand port device and three 10 mm laparoscopic ports (right-sided lesion)

stasis, and suturing. HALPN may need less laparoscopic learning curve than standard LPN. The results from the presented technique described in this communication are encouraging and it is believed that a better outcome can be obtained if more experience is gained.

Acknowledgement

The authors wish to thank Professor Amnuay Thithapandha for his help and advice concerning the preparation of this manuscript

References

1. Novick AC. Laparoscopic and partial nephrectomy. *Clin Cancer Res* 2004; 10: 6322S-7S.
2. McDougall EM, Clayman RV, Chandhoke PS, Kerbl K, Stone AM, Wick MR, et al. Laparoscopic partial nephrectomy in the pig model. *J Urol* 1993; 149: 1633-6.
3. Winfield HN, Donovan JF, Godet AS, Clayman RV. Laparoscopic partial nephrectomy: initial case report for benign disease. *J Endourol* 1993; 7: 521-6.
4. Gill IS, Delworth MG, Munch LC. Laparoscopic retroperitoneal partial nephrectomy. *J Urol* 1994; 152: 1539-42.
5. McDougall EM, Elbahnasy AM, Clayman RV. Laparoscopic wedge resection and partial nephrectomy - the Washington University experience and review of the literature. *JSLs* 1998; 2: 15-23.
6. Harmon WJ, Kavoussi LR, Bishoff JT. Laparoscopic nephron-sparing surgery for solid renal masses using the ultrasonic shears. *Urology* 2000; 56: 754-9.
7. Rassweiler JJ, Abbou C, Janetschek G, Jeschke K. Laparoscopic partial nephrectomy. The European experience. *Urol Clin North Am* 2000; 27: 721-36.
8. Shekarriz H, Shekarriz B, Upadhyay J, Burk C, Wood DP Jr, Bruch HP. Hydro-jet assisted laparoscopic partial nephrectomy: initial experience in a porcine model. *J Urol* 2000; 163: 1005-8.
9. McGinnis DE, Strup SE, Gomella LG. Management of hemorrhage during laparoscopy. *J Endourol* 2000; 14: 915-20.
10. Barret E, Guillonneau B, Cathelineau X, Validire P, Vallancien G. Laparoscopic partial nephrectomy in the pig: comparison of three hemostasis techniques. *J Endourol* 2001; 15: 307-12.
11. Yoshimura K, Okubo K, Ichioka K, Terada N, Matsuta Y, Arai Y. Laparoscopic partial nephrectomy with a microwave tissue coagulator for small renal tumor. *J Urol* 2001; 165: 1893-6.
12. Gettman MT, Bishoff JT, Su LM, Chan D, Kavoussi LR, Jarrett TW, et al. Hemostatic laparoscopic partial nephrectomy: initial experience with the radiofrequency coagulation-assisted technique. *Urology* 2001; 58: 8-11.
13. Elashry OM, Wolf JS Jr, Rayala HJ, McDougall EM, Clayman RV. Recent advances in laparoscopic partial nephrectomy: comparative study of electro-surgical snare electrode and ultrasound dissection. *J Endourol* 1997; 11: 15-22.
14. Wolf JS Jr, Seifman BD, Montie JE. Nephron sparing surgery for suspected malignancy: open surgery compared to laparoscopy with selective use of hand assistance. *J Urol* 2000; 163: 1659-64.
15. Stifelman MD, Sosa RE, Nakada SY, Shichman SJ. Hand-assisted laparoscopic partial nephrectomy. *J Endourol* 2001; 15: 161-4.
16. Gill IS, Desai MM, Kaouk JH, Meraney AM, Murphy DP, Sung GT, et al. Laparoscopic partial nephrectomy for renal tumor: duplicating open surgical techniques. *J Urol* 2002; 167: 469-7.
17. Wolf JS Jr. Hand-assisted laparoscopy: pro. *Urology* 2001; 58: 310-2.
18. Gill IS. Hand-assisted laparoscopy: con. *Urology* 2001; 58: 313-7.
19. Stifelman MD, Sosa RE, Nakada SY, Shichman SJ. Hand-assisted laparoscopic partial nephrectomy. *J Endourol* 2001; 15: 161-4.
20. Herrell SD. Laparoscopic partial nephrectomy techniques: developments and translation. *J Urol* 2004; 172: 2553-6.
21. Brown JA, Hubosky SG, Gomella LG, Strup SE. Hand assisted laparoscopic partial nephrectomy for peripheral and central lesions: a review of 30 consecutive cases. *J Urol* 2004; 171: 1443-6.
22. Wolf JS Jr, Moon TD, Nakada SY. Hand assisted laparoscopic nephrectomy: comparison to standard laparoscopic nephrectomy. *J Urol* 1998; 160: 22-7.

การผ่าตัดเนื้อไตแบบบางส่วนในผู้ป่วยมะเร็งเนื้อไตโดยใช้การผ่าตัดผ่านกล้องร่วมกับการใช้มือช่วย:
รายงานแรกในประเทศไทย

กิตติณัฐ กิจวิทย์, อภิษฐ์ ทองดอนนบม, วชิร คชการ

รายงานการผ่าตัดเนื้อไตแบบบางส่วนในผู้ป่วยมะเร็งเนื้อไต โดยใช้การผ่าตัดผ่านกล้องร่วมกับการใช้มือช่วย สำเร็จเป็นรายแรกของคณะแพทยศาสตร์โรงพยาบาลรามาธิบดี และเป็นรายงานแรกในประเทศไทย โดยมีการวิเคราะห์เกี่ยวกับเทคนิคการผ่าตัด และผลการรักษา ซึ่งผลการรักษาของผู้ป่วยโดยเทียบเคียงกับวรรณกรรมต่างประเทศ ที่รายงานก่อนหน้านี้ที่มีจำนวนมากที่สุดพบว่า การสูญเสียโลหิต ระยะเวลาการผ่าตัด ใกล้เคียงกัน และไม่พบภาวะแทรกซ้อนที่เป็นอันตราย
