

# Significance of Muscularis Mucosae in Metastasis Involvement of Urinary Bladder Transitional Cell Carcinoma

Suchart Chaimuangraj MD\*,  
Charuspong Dissaranan MD\*, Charoen Leenanupunth MD\*,  
Prapapan Prathombutr RN\*\*, Panas Chalernsanyakorn MD\*\*\*

\* Urology Division, Department of Surgery, Faculty of Medicine, Ramathibodi Hospital, Mahidol University

\*\* Department of Nursing, Faculty of Medicine, Ramathibodi Hospital, Mahidol University

\*\*\* Department of Pathology, Faculty of Medicine, Ramathibodi Hospital, Mahidol University

---

**Objective:** To assess the significance of muscularis mucosae involvement in metastasis of urinary bladder transitional cell carcinoma.

**Material and Method:** This was a retrospective cohort study of superficial urothelial carcinoma (transitional cell carcinoma). Histopathology and patient records of 192 patients were collected from 1990 to 2004. There were 115 males and 77 females, their age ranged from 43 to 83 years old with an average of  $60 \pm 5$  years. One hundred cases did not invade muscularis mucosae layer (group A) and 92 cases invaded the muscularis mucosae layer (group B). The histopathology of biopsy or cystectomy specimens for recurrence, progression of the disease and the number of vessels above and below the muscularis mucosae layer of bladder cancer specimens were compared by light microscopic examination with Hematoxylin and Eosin (H&E) and followed by immunoperoxidase desmin stain.

**Results:** The amount per high power field of the blood and lymphatic vessels below muscularis mucosae layer, 9 (6-12), was significantly higher than that above muscularis mucosae layer, 7 (5-10) ( $p < 0.05$ ). The cancer high grade (grade 3) in group B had also significantly higher percentage than that in group A, 30.4:5.0 ( $p < 0.05$ ). Moreover, the recurrent rate (recurrent  $> 2$ ) in group B had also a significantly higher percentage than that in group A, 21.4:4.0 ( $p < 0.05$ ).

**Conclusion:** The present study has confirmed previous findings that not all muscularis mucosae layers (about 50%) were found in the biopsy specimens. The findings of superficial urothelial cancer (no invasion to muscularis propria) invading the muscularis mucosae are a warning sign for invasive tumor that needs more aggressive treatment.

**Keywords:** Muscularis mucosae, Urothelial cancer, Transitional cell carcinoma, Recurrence, Urinary bladder

**J Med Assoc Thai 2006; 89 (9): 1447-53**

**Full text. e-Journal:** <http://www.medassocthai.org/journal>

---

In general, the management of urothelial cancer (transitional cell carcinoma) depends on the staging of the disease. According to Jewett-Strong-Marshall and UICC Classification<sup>(1)</sup>, the superficial group is the tumor found at A or T<sub>1</sub>, whereas the inva-

sive group is found at B or T<sub>2</sub>. In other words, the superficial group involves the epithelium to muscularis propria (detrusor muscle) while the invasive group takes on the muscularis propria downwards and may be locally invasive only in the urinary bladder or has already been spread to other distant organs or lymphatic system.

It is important to classify the tumor as superficial or invasive because its control and management are more aggressive in the invasive stage than in the

---

Correspondence to : Chaimuangraj S, Division of Urology, Department of Surgery, Faculty of Medicine, Ramathibodi Hospital, Mahidol University, Bangkok 10400, Thailand. Phone: 0-2201-1315, Fax: 0-2201-1316, E-mail: rascm@mapraw.com, rascm@mahidol.ac.th

superficial stage. In the superficial stage, the tumor is removed by transurethral resection (TUR-BT) and successive instillation of intravesical chemotherapy or immunotherapy<sup>(2)</sup>. However, in an invasive stage, the bladder may be sacrificed and regional radiotherapy or systemic chemotherapy may have to be given for adequate control of the disease<sup>(3,4)</sup>.

From light microscopic histopathological examination, it is known that the distribution of blood and lymphatic vessels in the so-called muscularis mucosae is not homogenous. A thin layer of muscle known as muscularis mucosae lying in the lamina propria separates a significant number of vessels from the more superficial area. The invasiveness of the tumor may be indicated by the extent of invasion of the vessels.

The objective of the present communication was to determine the difference of the recurrent rate and grading of the urinary bladder transitional cell carcinoma as well as the difference in the density of the blood and lymphatic vessels above and below the muscularis mucosae.

#### Material and Method

Tissue specimens from biopsy or cystectomy of cancer patients with transitional cell carcinoma were obtained surgically from the bladder at the layer above the muscularis propria or detrusor muscle. One hundred and ninety two patients were admitted for surgical examinations at Ramathibodi Hospital from 1990 to 2004. Their age range was 43 to 83 years and the average age was  $60 \pm 5$  years. There were 115 males and 77 females (Table 1). The study protocol was approved by the Institutional Review Board and Department of Surgery, Faculty of Medicine, Ramathibodi Hospital, Mahidol University.

The tissue specimens were divided into two groups. Group A comprised tumor specimens (from 100 patients) from above the muscularis mucosae and those in whom this layer could not be detected. Group B specimens (from 92 patients) were from the tumor lying below the muscularis mucosae but not in muscularis

**Table 1.** Demographic data of the patients (n = 192) from 1990-2004

Total number of patients	192
Male : Female	115:77 (3:2)
Age range (yr)	43-83
Average age (mean $\pm$ SD, yr)	$60 \pm 5$
Ratio of number of patients for tumors above (A) to that below (B) muscularis mucosae	100:92

propria. The specimens were prepared for light microscopic examination at the magnification of 40 and 200 by Hematoxylin and Eosin (H&E) staining, followed by immunoperoxidase desmin to locate the muscularis mucosae and determine the number of blood and lymphatic vessels as well as grading of the tumor above and below this layer. The recurrence number of tumor invading muscularis mucosae was also compared with that of the non-invading tumor to muscularis mucosae. Recurrent rates and grades of the tumor were reviewed and followed from hospital medical and digital pathological records for 2 - 7 years.

All statistical analyses in the present study were performed by using SPSS version 12. Wilcoxon Signed Ranks Test was employed to test the significant difference between the number of blood and lymphatic vessels above and that below the muscularis mucosae, whereas the X<sup>2</sup>-test and F-test were used to determine the association between tumor grades and its invasion into muscularis mucosae and also the recurrent rate of both group A and group B. A p-value of less than 0.05 was considered significant.

#### Results

From light microscopic histopathological examination it was found that the distribution of blood and lymphatic vessels in the so-called muscularis mucosae was not homogenous. The number of blood and lymphatic vessels above (n = 40) and below (n = 40) muscularis mucosae of the same histopathological specimens from group A and group B were 7 (5-10) and 9 (6-12), which were found to be statistically significantly different ( $p < 0.05$ ). The comparison of the vessels above and below the muscularis mucosae among each group was also significantly different ( $p < 0.05$ ). However, there was no significant difference in the number of vessels of the above or below muscularis mucosae of the two groups ( $p = 0.336$ ,  $p = 0.361$ ) (Table 2).

There was an association between grade of the urinary bladder transitional cell carcinoma and invasion to muscularis mucosae. The lower grade (grade 1) urinary bladder transitional cell carcinoma was more common among above muscularis mucosae cases (group A, 42.0%) than below muscularis mucosae cases (group B, 9.8%) ( $p < 0.001$ ). However, on the contrary, the high grade (grade 3) urinary bladder transitional cell carcinoma was more in group B (5.0%) than group A (30.4%) ( $p < 0.001$ ). Accordingly, the moderate grade (grade 2) was not different in percentage between both group A (53.0%) and B (59.8%) ( $p = 0.342$ ) (Table 3).

All cases were followed for urinary bladder cancer recurrent rates by histopathological digital records from the department of pathology and hospital medical records for 2 - 7 years after the first histopathological diagnosis. In the non-recurrent cases (recurrent = 0), group A (45%) was more common than group B (17.4%) ( $p < 0.001$ ) but for the high recurrent cases (recurrent = 2), group B (22.8%) was a higher than group A (8.0%) ( $p = 0.004$ ). There was an even more different percentage in the higher recurrent cases (recurrent > 2) that group B (21.7%) was higher than group A (4.0%) ( $p = 0.001$ ). Thus, the recurrence of urinary bladder cancer was statistically, significantly different between

above muscularis mucosae (group A) and below muscularis mucosae (group B) in non-recurrent and also in high recurrent cases (recurrent  $\geq 2$ ). For the low recurrent cases (recurrent = 1) the percentage in group A (43.0%) and B (38.1%) was not different ( $p > 0.484$ ) (Table 4).

### Discussion

There are several prognostic markers proposed for urinary bladder urothelial tumor such as DNA content (ploidy), cellular proliferation, nuclear morphometry, p53 suppressor gene, basement membrane status and angiogenetic factors. However, in light

**Table 2.** Total number of blood and lymphatic vessels above and below muscularis mucosae (MM) of the same histopathological specimens from cancer of the bladder above MM (n = 20) and cancer of the bladder below MM (n = 20)

	CA Bladder above MM (n = 20)	CA Bladder below MM (n = 20)	Total (n = 40)	p*
No. Vessels Above MM	8 (5-10) <sup>a</sup>	7 (6-10) <sup>a</sup>	7 (5-10) <sup>a</sup>	0.336
No. Vessels Below MM	9 (8-12)	9 (6-11)	9 (6-12)	0.361
p*	0.007	0.002	0.000	

a : Statistically significant difference between number of vessels above muscularis mucosae and number of vessels below muscularis mucosae, Median (min-max)

: No statistically significant difference among number of vessels above muscularis mucosae in the study group

: No statistically significant difference among the number of vessels below muscularis mucosae in the study group

p\* Wilcoxon Signed Ranks Test

**Table 3.** Correlation between grade of urinary bladder transitional cell carcinoma (TCC) and its invasion to muscularis mucosae (MM)

Grade of TCC	Without TCC invasion to MM (Group A) (n = 100)	With TCC invasion to MM (Group B) (N = 92)	p (X <sup>2</sup> -test)	p (Z-test)
1	42.0 (42)	9.8 (9)	<0.001	<0.001
2	53.0 (53)	59.8 (55)		0.342
3	5.0 (5)	30.4 (28)		<0.001

Results are expressed as percent, with the actual number shown in parenthesis

**Table 4.** Correlation between recurrent rate of urinary bladder transitional cell carcinoma (TCC) and its invasion to muscularis mucosae (MM)

No. of Recurrence of TCC	Without TCC invasion to MM (Group A) (n = 100)	With TCC invasion to MM (Group B) (n = 92)	p (X <sup>2</sup> -test)	p (Z-test)
0	45.0 (45)	17.4 (16)	<0.001	<0.001
1	43.0 (43)	38.1 (35)		0.484
2	8.0 (8)	22.8 (21)		0.004
> 2	4.0 (4)	21.7 (20)		0.001

Results are expressed as percent, with the actual number shown in parenthesis

microscopic examination, the grade and pathological stage are the mainstays for diagnosis and prognosis of the diseases.

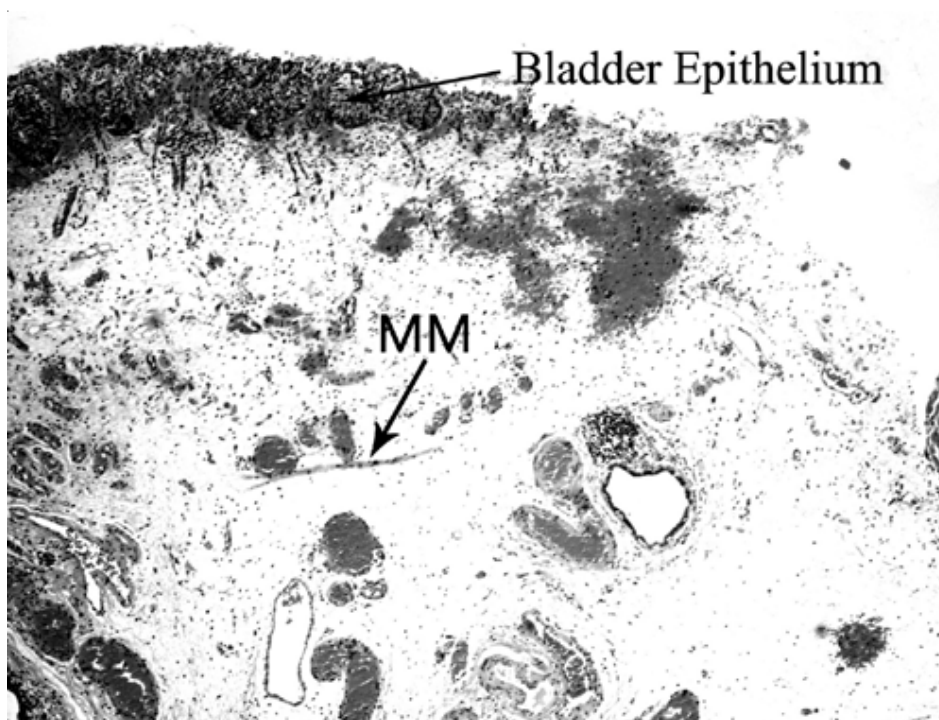
Muscularis mucosae were first described by Dixon and Gosling in 1983. It is a thin muscle layer lying in lamina propria, superficial to the muscularis propria (detrusor muscle) and can be detected in 35 to 82% of the bladder specimens in complete or near complete form, and mostly appear in a scattering muscle fiber<sup>(5,6)</sup>. Although the results were not shown here, it was found from the autopsy specimens in Thai patients without bladder cancer that the muscularis mucosae appeared in 20 out of 46 cases (43.5%). This incidence is similar to that reported in the literature<sup>(5,6)</sup>. In some areas of the bladder, such as trigone, the muscularis mucosae may be difficult to identify from the muscularis propria<sup>(7)</sup>.

It has been known that the deeper the invasion of urinary transitional cell carcinoma, the higher the chance of distant metastasis<sup>(3)</sup>. Some histopathological examinations of cold cup biopsy or Trans Urethral Resection of Bladder Tumor (TURBT) tissue may not be adequately deep into the detrusor muscle or muscularis propria layer and leads to incomplete tumor staging.

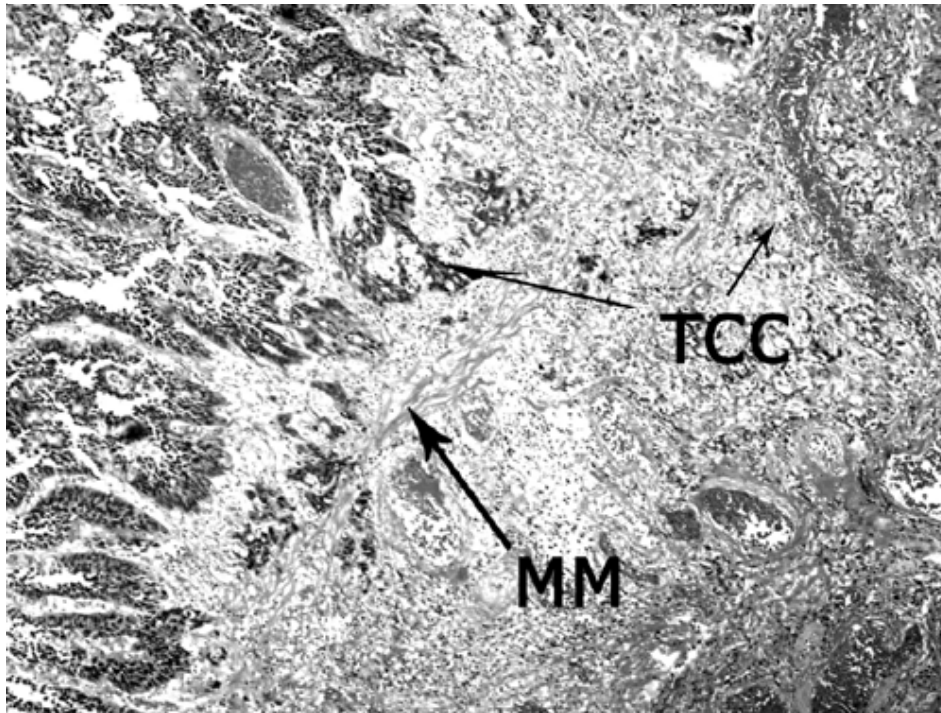
Of the two groups: group A, and group B, there was a significant number of vascular and lymphatic vessels lying scattered below (9 (6-12) more than above the muscularis mucosae layer (7 (5-10),  $p < 0.05$ ) (Table 4 and Fig. 1-3). This means there was an increased in chance of metastasis, if the cancer would have invaded the area below, than the same cancer invading the area above muscularis mucosae.

The present study also showed that cancer populations in the below muscularis mucosae were more common in the higher grade (grade 3) than the above (gr.A 5.0: gr.B 30.4,  $p < 0.001$ ) and also less common in the lower grade (grade 1) than the above muscularis mucosae (gr.A 42.0: gr.B 9.8,  $p < 0.001$ ) (Table 3). Thus, the more aggressive urinary bladder urothelial tumors are more common in the deeper area than in the superficial part of the muscularis mucosae.

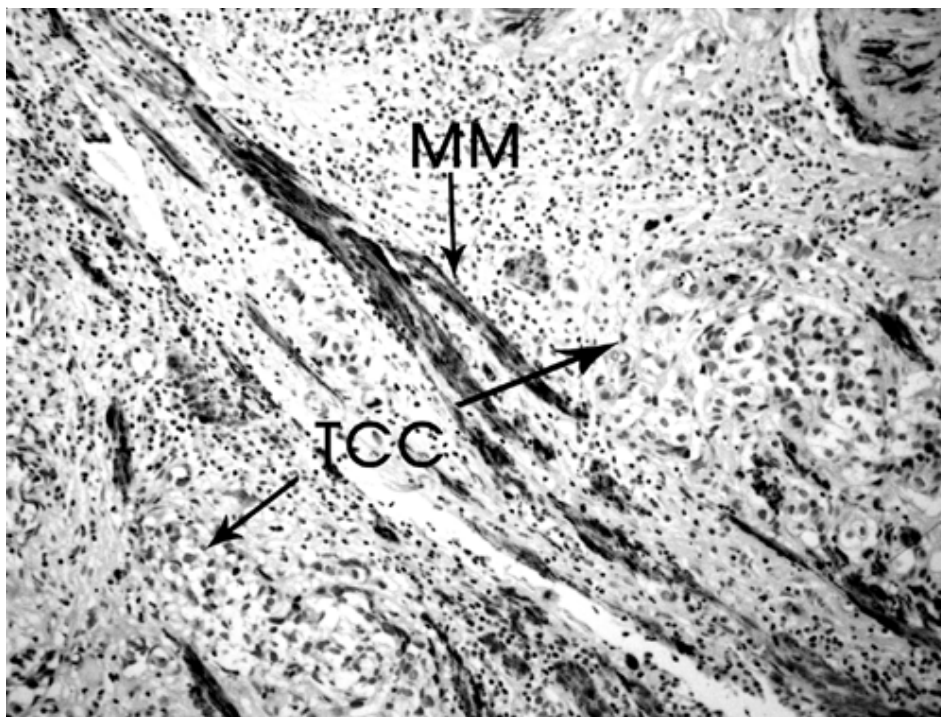
As mentioned above, the recurrent rates and grades of the tumor were reviewed and followed from the medical and digital pathological records. The present study showed that the higher urinary bladder urothelial tumor recurrent rate (more than two times of recurrence) of the deeper group (group B) had a higher percentage than the superficial group (group A) (gr.A



**Fig. 1** Hematoxylin and Eosin (H&E) stain of normal histologic picture of bladder wall showing a thin layer of muscularis mucosae lying in the lamina propria (H&E light microscope x 40)



**Fig. 2** Hematoxylin and Eosin (H&E) stain of urothelial cancer (transitional cell carcinoma) of the bladder invading to the lamina propria (H&E light microscope x 40)



**Fig. 3** Immunoperoxidase with desmin stain of urothelial cancer (transitional cell carcinoma) of the bladder invading to the lamina propria showing a thin layer of muscularis mucosae in brown (immunoperoxidase light microscope x 200)

4.0: gr.B 21.7,  $p < 0.05$ ). In contrast, the lower urinary bladder urothelial tumor recurrent rate (no recurrence) of group B had less percentage than group A (gr.A 45.0: gr.B 17.4,  $p < 0.05$ ). These findings thus suggested that the deeper urinary bladder urothelial tumor group (group B) had more chance of recurrence than the more superficial group, (group A). This finding was in agreement with those of other previous studies<sup>(8-10)</sup>.

Muscularis mucosae layer is not found in all bladder specimens and this leads to the agreement of not accepting the classification of bladder tumor stage T<sub>1</sub> to T<sub>1a</sub> and T<sub>1b</sub><sup>(11)</sup>. However, it is proposed that a depth of 1.5 mm, as measured by an ocular micrometer, may help determine the proper depth of the early dangerous zone in case of no muscularis mucosae layer identified<sup>(12)</sup>.

It is interesting to note that in a book published by the World Health Organization classification of tumors 2004, it mentions the invasive stage of bladder urothelial cancer (transitional cell carcinoma) when the tumor invades beyond the basement membrane that is lying under the epithelial tissue<sup>(13)</sup>. The above statement has led to the conclusion that radical surgery to eradicate the tumor will be much higher in incidence than the presently accepted classification.

It is an on going correlation study between non-detrusor muscle invasion of urothelial tumor below muscularis mucosae (group B) and that of detrusor muscle invaded by the tumor. It is also interesting to study if muscularis mucosae is also a significant prognostic histologic marker for other bladder epithelial cancers, such as adenocarcinoma or squamous cell carcinoma.

### Conclusion

The study of 192 Thai patients at Ramathibodi Hospital showed that the non-detrusor muscle invasive bladder urothelial cancer (transitional cell carcinoma) that invaded the muscularis mucosae was potentially more aggressive than that of non-muscularis mucosae invasion. The former group, muscularis mucosae invasion, had a significantly higher grade and higher recurrent rate than the latter. The more vascular densities below muscularis mucosae may be one of the contributing factors. This suggests that invasion of muscularis mucosae of urothelial cancer is a warning sign for early and aggressive cancer control and surveillance.

### Acknowledgements

The authors wish to thank Professor Amnuay

Thithapandha for his help and advice during the preparation of this manuscript, and also to Mrs. Umaporn Udomsubpayakul for her help on data management and analysis.

### References

1. UICC. TNM. Available at: <http://www.uicc.org>. TNM
2. van der Meijden AP, Boehle A, Oosterlinck W, Lobel B, Rintala E, Solsona E, et al. Recommendation from the EAU Working Party on Superficial Bladder Cancer. *Eur Urol* 2002; 41: 105-12.
3. Edward MM. Urothelial tumours of the urinary tract: bladder cancer. In: Walsh PC, Retik AB, Vaughan ED, editors. *Campbell's urology*. 8th ed. Philadelphia: WB Saunders; 2003: 2732-844.
4. Holmang S, Hedelin H, Anderstrom C, Holmberg E, Johansson SL. The importance of the depth of invasion in stage T1 bladder carcinoma: a prospective cohort study. *J Urol* 1997; 157: 800-3.
5. Weaver MG, Abdul-Karim FW. The prevalence and character of the muscularis mucosae of the human urinary bladder. *Histopathology* 1990; 17: 563-6.
6. Keep JC, Piehl M, Miller A, Oyasu R. Invasive carcinomas of the urinary bladder. Evaluation of tunica muscularis mucosae involvement. *Am J Clin Pathol* 1989; 91: 575-9.
7. Dixon JS, Gosling JA. Histology and fine structure of the muscularis mucosae of the human urinary bladder. *J Anat* 1983; 136: 265-71.
8. Narayana AS, Loening SA, Slymen DJ, Culp DA. Bladder cancer: factors affecting survival. *J Urol* 1983; 130: 56-60.
9. Anderstrom C, Johansson S, Nilsson S. The significance of lamina propria invasion on the prognosis of patients with bladder tumors. *J Urol* 1980; 124: 23-6.
10. Angulo JC, Lopez JI, Grignon DJ, Sanchez-Chapado M. Muscularis mucosa differentiates two populations with different prognosis in stage T1 bladder cancer. *Urology* 1995; 45: 47-53.
11. Epstein JI, Amin MB, Reuter VR, Mostofi FK. The World Health Organization/International Society of Urological Pathology consensus classification of urothelial (transitional cell) neoplasms of the urinary bladder. Bladder Consensus Conference Committee. *Am J Surg Pathol* 1998; 22: 1435-48.
12. Cheng L, Neumann RM, Weaver AL, Spotts BE, Bostwick DG. Predicting cancer progression in patients with stage T1 bladder carcinoma. *J Clin Oncol* 1999; 17: 3182-7.

13. Lopez-Beltran A, Knowles MA, Sauter G. Infiltrating urothelial carcinoma. In: Eble JN, Sauter G, Jonathan I, Epstein MD, editors. World Health

Organization Classification of Tumors: Pathology and genetics. Tumors of the urinary system and male genital organs. Lyon: IARC Press; 2004: 90-109.

---

### ความสำคัญของชั้นกล้ามเนื้อลิวอิส มิวโคซี ต่อการลุกลามของมะเร็งเยื่อบุทวารานติชั้นของกระเพาะปัสสาวะ

สุชาติ ไชยเมืองราช, จรัสพงศ์ ดิศรานันท์, เจริญ ลีนาอนุพันธุ์, ประภาพรรณ ประถมบุตร, พันธ์ เฉลิมแสนยาก

**วัตถุประสงค์:** เพื่อศึกษาความสำคัญของชั้นกล้ามเนื้อลิวอิส มิวโคซี ต่อการลุกลามของมะเร็งเยื่อบุทวารานติชั้นของกระเพาะปัสสาวะ

**วัสดุและวิธีการ:** เป็นการศึกษาชนิด Retrospective cohort จากเนื้อเยื่อ biopsy หรือ cystectomy ของมะเร็งกระเพาะปัสสาวะชนิด transitional cell carcinoma ระหว่างปี พ.ศ. 2533-2547 จากผลการตรวจเนื้อเยื่อ และจากเวชระเบียนผู้ป่วยจำนวน 192 ราย เป็นชาย 115 ราย: หญิง 77 ราย อายุเฉลี่ย  $60 \pm 5$  ปี ซึ่งเป็นพวกที่ได้รับ การวินิจฉัยครั้งแรกว่า ยังไม่แพร่กระจายเข้าหรือไม่พบชั้น muscularis mucosae (กลุ่ม A) จำนวน 100 ราย และ พวกที่แพร่กระจายเข้าใต้ชั้น muscularis mucosae แต่ยังไม่แพร่ขยายตัวเข้าชั้น muscularis propria (กลุ่ม B) จำนวน 92 ราย เพื่อศึกษาเปรียบเทียบ recurrent และ progression ของมะเร็ง และเปรียบเทียบปริมาณของเส้นเลือด และเส้นน้ำเหลืองที่อยู่เหนือและใต้ชั้น muscularis mucosae โดยการย้อมสี Hematoxylin and Eosin (H&E) และ ตามด้วย การย้อม immunoperoxidase desmin

**ผลการศึกษา:** พบว่า มีจำนวนเส้นเลือดฝอย และเส้นน้ำเหลือง ที่อยู่ใต้ชั้น muscularis mucosae 9 (6-12) มากกว่า อยู่เหนือชั้น muscularis mucosae 7 (5-10) ( $p < 0.05$ ) สำหรับเนื้อเยื่อในกลุ่ม B เมื่อเปรียบเทียบกับ เนื้อเยื่อในกลุ่ม A นั้น กลุ่ม B มีความสัมพันธ์กับมะเร็ง grade สูง (grade 3) (ร้อยละ 30.4) มากกว่ากลุ่ม A (ร้อยละ 5.0) ( $p < 0.05$ ) และกลุ่ม B มีความสัมพันธ์กับการเกิดซ้ำบ่อย (recurrent  $> 2$ ) (ร้อยละ 21.4) มากกว่า กลุ่ม A (ร้อยละ 4.0) ( $p < 0.05$ )

**สรุป:** ถึงแม้ว่าชั้น muscularis mucosae พบได้ในเนื้อเยื่อนำมาตรวจเพียงประมาณร้อยละ 50 แต่จากการศึกษา นี้แสดงข้อควรระวังว่า เมื่อพบมะเร็งชนิดนี้ในระยะ Superficial ที่ได้แพร่กระจายเข้าชั้น muscularis mucosae แล้ว (ไม่พบการเข้าชั้น muscularis propria) จะเป็นมะเร็งที่มีความรุนแรงกว่า คือ grade สูงกว่า และมี recurrence ได้บ่อยกว่า และมีจำนวนเส้นเลือดและน้ำเหลืองที่อยู่ต่ำกว่าชั้น muscularis mucosae มากกว่า จึงควรจะรีบให้การรักษา อย่างพอเพียงและเร็วขึ้น มากกว่ากลุ่มที่ไม่ได้แพร่กระจายเข้าชั้นนี้ ทั้งนี้เพื่อการควบคุมและป้องกันการลุกลามของมะเร็งให้ได้ผลดีที่สุด