

Case Report

Thai Girl with Ring Chromosome 18 (46XX, r18)

Rosawan Sripanidkulchai MD*, Chanyut Suphakunpinyo MD*,
Charoon Jetsrisuparb MD**, Saman Luengwattanawanich BSc***

* Ambulatory Pediatrics Unit, Department of Pediatrics, Faculty of Medicine, Khon Kaen University, Khon Kaen

** Dermatology Pediatrics Unit, Department of Pediatrics, Faculty of Medicine, Khon Kaen University, Khon Kaen

*** Cytogenetic Unit, Department of Pathology, Faculty of Medicine, Khon Kaen University, Khon Kaen

Chromosomal anomalies occur in 0.4% of live births. Ring chromosomes have been found for all human chromosomes and when it is replacing a normal chromosome, it results as a partial monosomy. The phenotype often overlaps that seen in comparable deletion syndromes of the same chromosomes. In the present report the authors describe the clinical manifestations of a girl with ring chromosome 18 (46XX,r18) including dysmorphic features, failure to thrive, global delay of development, hypothyroidism, atopic dermatitis, bilateral chronic otitis media, aortic regurgitation with patent foramen ovale and immunoglobulin A deficiency.

Keywords: Ring chromosome 18, Thailand, Pediatric, IgA deficiency, Mental retardation

J Med Assoc Thai 2006; 89 (6): 878-81

Full text. e-Journal: <http://www.medassocthai.org/journal>

Chromosomal anomalies occur in 0.4% of live births⁽¹⁾. They are an important cause of mental retardation and congenital anomalies. Chromosome anomalies are found in number and structure. Abnormalities of chromosome structure include deletions, translocations, inversions, ring chromosomes, duplications and insertions. Formation of a ring chromosome involves a deletion at each end of the chromosome then the "sticky" ends join to form a ring. Though it is rare, ring chromosomes have been found for all human chromosomes. When it replaces a normal chromosome, it results in a partial monosomy. The phenotype often overlaps that seen in comparable deletion syndromes of the same chromosomes. In the present report, the authors describe the clinical manifestations of a girl with ring chromosome 18.

Case Report

A 2 year old girl presented with a history of chronic eczema and chronic otitis media for 1 year. She had failure to thrive and delayed developmental milestones. Physical examination revealed an active

dysmorphic child with light brown hair. Dysmorphic features included a flattened forehead; deep-set eyes, hypotelorism, bilateral ptosis, low set ears, high arch palate, protrusion of the maxilla and micrognathia. Her height, weight and head circumference, 65 cm, 5.3 kg and 39 cm were all less than the 3rd percentile. The anterior fontanel was 1.5 x 1.5 cm, the posterior fontanel had closed. Purulent discharge was seen in both ear canals. Her nipples were widely spaced. She had a systolic ejection murmur of grade III/VI at her left upper parasternal boarder. On abdominal examination, mild hepatomegaly and an umbilical hernia were noted. She had ulnar deviation of hands, genu valgum and over riding of 2nd finger over 1st toes in both feet. Her skin was dry with fine scales at the forehead, erythematous papules with crust and serum oozing and scales at the flexor area of all extremities.

She was a near term baby delivered by normal labor at 36 weeks of gestational age. The birth weight was 2100 gm. During the neonatal period she required admission due to jaundice and poor feeding, she received 4 days of phototherapy and was fed via orogastric tube feeding during and after discharge. The total admission period was 2 months. She was the third child of a 38 year old mother and 26 year old father; their first 2 children 11-year-old son and 9-year-old daughter were all healthy.

Correspondence to : Sripanidkulchai R, Department of Pediatrics, Faculty of Medicine, Srinagarind Hospital, Khon Kaen University, Khon Kaen 40002, Thailand. Phone: 0-4336-3012, Fax: 0-4334-8382, E-mail: rosawan@kku.ac.th

Blood samples revealed fasting blood sugar; 72 mg/dl, TSH; 0.05 (0.4-3.1 mIU/ml), FT4; 0.4 (0.86-1.87 ng/dl). Her serum Immunoglobulin levels were; IgG 2407.77 (1244-1888), IgM 186.79 (104-202), IgA < 40.69 (80-240). At the age of 2 years old, her bone age corresponded with the age of 6 months. Mild hepatomegaly and bilateral renal parenchymal disease were seen on abdominal ultrasonography. On cardiologic evaluation, sinus tachycardia with heart rate of 160 beats per minute and QRS axis of 240° were present on electrocardiography. Echocardiography findings included patent foramen ovale 0.36 cm in diameter with left to right flow, aortic valve regurgitation with pressure gradient 13.4 mmHg and EF 59.4%. She had global delay of development. Despite her age, her average abilities were equal to a 4 month old child. The personal-social aspect was equal to 5 months, fine motor 4 months, language 3

months and gross motor 5 months. Karyotype analysis using G-banding technique (Fig. 1) resulted as 46XX,r18.

The diagnosis of ring chromosome 18 was made, with failure to thrive, global delay of development, hypothyroidism, atopic dermatitis, bilateral chronic otitis media, aortic regurgitation with patent foramen ovale, and immunoglobulin A deficiency. After admission and further workup, she was treated with antibiotics for chronic otitis media, the pus cultures were positive for *P. aeruginosa*. Thyroid hormone was supplemented. Her skin lesions improved after treatment with topical corticosteroids.

Discussion

There are no reports on clinical manifestations of Thai patients with ring chromosome 18. The

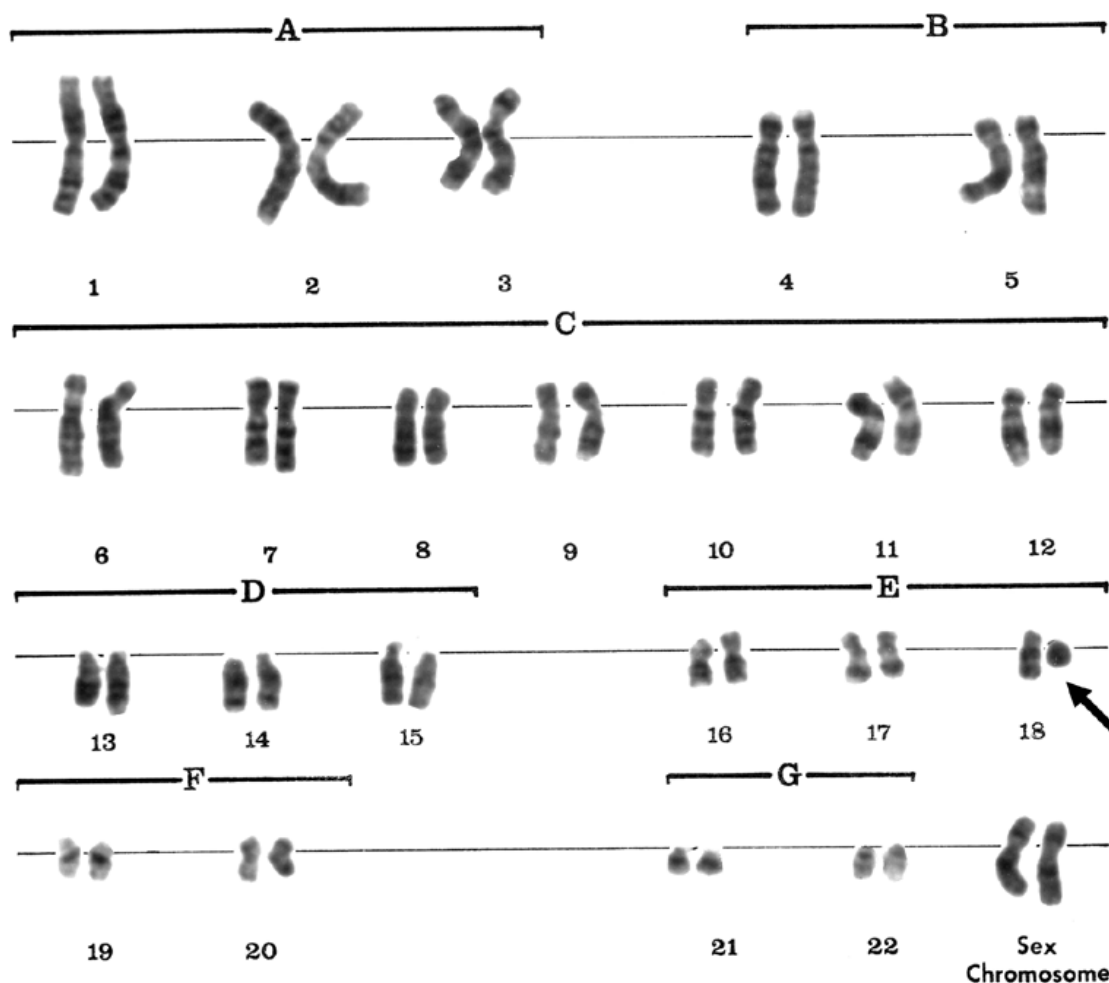


Fig 1. Patient's Karyotype analysis by G-banding technique, the arrow indicates the ring chromosome

authors describe the clinical manifestations of a Thai girl with ring chromosome 18 (46XX,r18). The syndrome of ring chromosome 18 results from deletions at both ends of the chromosome, then the joining of the ends of the p and q arms back together. There is chromosome material lost from both arms. Individuals with ring chromosome 18 have a combination of 18p deletion and 18q deletion⁽²⁻⁷⁾. This corresponds with the parts of the chromosome that are deleted. All features of this syndrome have been described in someone with 18p deletion or 18q deletion⁽⁸⁾. This patient shares clinical manifestations of both chromosome 18p and 18q deletion syndrome (Tables 1⁽⁹⁾ and 2⁽¹⁰⁾), though correlated with chromosome 18q deletion syndrome more than chromosome 18p deletion syndrome.

Hypothyroidism has been reported in ring chromosome 18 syndrome^(3,11,12). The presented patient had delayed development and delayed bone age that corresponded with secondary hypothyroidism and ring chromosome 18 syndrome. Growth hormone deficiency, also reported in this syndrome^(13,14), could be another cause of the failure to thrive. However, in the presented patient growth hormone studies were not done due to economic causes. Other autoimmune endocrinopathies reported with this syndrome, such as insulin dependent diabetes mellitus⁽³⁾ was not detected in the presented patient. Immunoglobulin A deficiency

Table 1. Clinical features of chromosome 18p deletion syndrome in this patient⁽⁹⁾

Head and neck	brachycephaly and micrognathia
Mouth and oral structures	highly arched palate
Skin	eczema
Cardiovascular system	atrial and auricular septal defect
Immunologic system	immunoglobulin A deficiency
Growth and development	growth and mental retardation

Table 2. Clinical features of chromosome 18q deletion syndrome in this patient⁽¹⁰⁾

Head and neck	microcephaly, brachycephaly, prognathism, midfacial hypoplasia
Eyes	deeply set eyes and hypotelorism
Mouth and oral structures	highly arched palate
Hand and foot	abnormal toes
Immunologic system	Immunoglobulin A deficiency
Growth and development	growth, speech, and mental retardation

which is frequently associated with ring chromosome 18 syndrome^(4,15) was also noted. This should be kept in mind, especially when considering the use of blood products in this patient group. Close follow up is indicated. Further cytogenetic studies, DNA analysis and Fluorescence In Situ Hybridization studies should be done to identify location of chromosomal breakpoints.

Acknowledgements

The authors wish to thank Professor Pagakrong Lumbiganon for assistance with the English-language presentation of the manuscript.

References

- Hall JG. Chromosomal clinical abnormalities. In: Behrman RE, Kliegman RM, Jenson HB, editors. Nelson textbook of pediatrics. 17th ed. Philadelphia: Saunders; 2003: 382-91.
- Christensen K, Friedrich U, Jacobsen P, Jensen K, Nielsen J, Tsuboi T. Ring chromosome 18 in mother and daughter. *J Ment Defic Res* 1970; 14: 49-67.
- Dacou-Voutetakis C, Sertedaki A, Maniatis-Christidis M, Sarri C, Karadima G, Petersen MB, et al. Insulin dependent diabetes mellitus (IDDM) and autoimmune thyroiditis in a boy with ring chromosome 18: additional evidence of autoimmunity or IDDM gene(s) on chromosome 18. *J Med Genet* 1999; 36: 156-8.
- Finley SC, Cooper MD, Finley WH, Uchida IA, Noto TA, Roddam RF. Immunological profile in a chromosome 18 deletion syndrome with IgA deficiency. *J Med Genet* 1969; 6: 388-93.
- Fryns JP, Kleczkowska A, Smeets E, Van Den Berghe H. Transmission of ring chromosome 18 46,XX/46,XX,r(18) mosaicism in a mother and ring chromosome 18 syndrome in her son. *Ann Genet* 1992; 35: 121-3.
- Fryns JP, Kleczkowska A. Autism and ring chromosome 18 mosaicism. *Clin Genet* 1992; 42: 55.
- United States National Library of Medicine and National Institutes of Health. Chromosome 18 ring syndrome, multiple congenital anomaly/mental retardation (MCA/MR) syndromes [online]. Available from: URL: <http://www.nlm.nih.gov/mesh/jablonski/syndromes/syndrome190.html>
- Chromosome 18 Registry & Research Society. Ring 18 syndrome description ring chromosome 18 syndrome [online]. Available from: URL: http://chromosome18.org/syndrome_ring.htm
- United States National Library of Medicine and

- National Institutes of Health. Chromosome 18p deletion syndrome, multiple congenital anomaly/mental retardation (MCA/MR) syndromes [online]. Available from: URL: <http://www.nlm.nih.gov/mesh/jablonski/syndromes/syndrome192.html>
10. United States National Library of Medicine and National Institutes of Health. Chromosome 18q deletion syndrome, multiple congenital anomaly/mental retardation (MCA/MR) syndromes [online]. Available from: URL: <http://www.nlm.nih.gov/mesh/jablonski/syndromes/syndrome194.html>
 11. Winter JS, Ahluwalia K, Ray M. Congenital hypothyroidism in association with a ring chromosome 18. *J Med Genet* 1972; 9: 122-6.
 12. Fukushima Y, Fukuda T, Kuroki Y, Niikawa N, Matsuura N, Yamada Y, et al. Predisposition to autoimmune thyroiditis in ring chromosome 18 syndrome. *Jinrui Idengaku Zasshi* 1984; 29: 127-32.
 13. Meloni A, Boccone L, Angius L, Loche S, Falchi AM, Cao A. Hypothalamic growth hormone deficiency in a patient with ring chromosome 18. *Eur J Pediatr* 1994; 153: 110-2.
 14. Abusrewil S, McDermott A, Savage DC. Growth hormone, suspected gonadotrophin deficiency, and ring 18 chromosome. *Arch Dis Child* 1988; 63: 1090-1.
 15. Litzman J, Brysova V, Gaillyova R, Thon V, Pijackova A, Michalova K, et al. Agammaglobulinemia in a girl with a mosaic of ring 18 chromosome. *J Paediatr Child Health* 1998; 34: 92-4.

รายงานผู้ป่วย; เด็กหญิงไทยที่มีโครโมโซมแท่งที่ 18 เป็นโครโมโซมวงแหวน 1 แท่ง (46XX, r18)

รศวันต์ ศรีพานิชกุลชัย, ชาญยุทธ ศุภคุณภิญโญ, จริญญา เจตศรีสุภาพ, สมาน เลืองวัฒนะวณิช

ความผิดปกติของโครโมโซมพบได้ 0.4% ของอัตราการเกิดมีชีพ การเกิดโครโมโซมวงแหวนพบได้ในทุกโครโมโซมของมนุษย์ การมีโครโมโซมวงแหวนแทนที่โครโมโซมปกติ 1 แท่ง ผู้ป่วยจะมีการแสดงออกเหมือนกลุ่มอาการที่มีการขาดหายไปของบางส่วนของโครโมโซมนั้น ๆ รายงานฉบับนี้ บรรยายลักษณะของผู้ป่วยเด็กหญิง อายุ 2 ปีที่มีโครโมโซมแท่งที่ 18 เป็นโครโมโซมวงแหวน 1 แท่ง (46XX, r18) ได้แก่ ตัวเล็ก เลี้ยงไม่โต พัฒนาการช้าทุกด้าน ภาวะขาดธัยรอยด์ฮอร์โมน ผื่นผิวหนังอักเสบภูมิแพ้ หูชั้นกลางอักเสบเรื้อรัง ลิ้นหัวใจเอออร์ติกรั่ว ผ่นกั้นหัวใจห้องบนรั่ว (patent foramen ovale) และมีระดับของ อิมมูโนโกลบูลิน เอ ต่ำ