

## Case Report

---

# Neuropathic Arthropathy of the Elbow: A Report of Two Cases

Aasis Unnanuntana MD\*,  
Saranatra Waikakul MD\*

\* Department of Orthopaedic Surgery, Siriraj Hospital, Mahidol University

---

**Background:** Neuropathic arthropathy (Charcot joint) of the elbow is a rare condition. It is among the least frequently reported Charcot pathology of the joint. The clinical symptoms are characterized by a painless and unstable joint. Infection in the neuropathic joint is rare. Only a limited number of cases have been reported in the literature. The authors present two cases of neuropathic arthropathy of the elbow. One of them was diagnosed as Septic neuropathic arthropathy.

**Material and Method:** Two patients with neuropathic arthropathy of the elbow (an infected and a non-infected case) were treated at our department. Both patients were over 60 years old. The underlying conditions associated with the arthropathy included combined median and ulnar neuropathy in the infected case and idiopathic in the non-infected case. Both of the patients had a history of specific trauma at the affected elbows. The radiographs of the elbows revealed dislocation, fracture fragmentation and some bony sclerosis. The management in the non-infected case aimed to maintain the function of the elbow with a short period of immobilization and physical therapy. For the infected case, the patient was treated successfully with systemic antibiotic, surgical debridement and a period of immobilization with an external fixator.

**Results:** The patients were followed-up for approximately 9 months for the non-infected and 2 years for the infected case. Both of them had painless and functional range of motion of the elbows in the most recent follow-up examination. For the infected case, the surgical incision healed well and there was no recurrent discharge from that affected elbow.

**Conclusion:** In the first case, with neuropathic arthropathy of the elbow, the investigations were made to find the underlying disease. The second case with septic neuropathic joint, systemic antibiotic, surgical debridement and appropriate immobilization were needed. With gross instability and marked distortion of the joint, the elbow of both patients functioned remarkably well.

**Keywords:** Neuropathic arthropathy, Charcot joint, Elbow, Septic, Infected joint, Idiopathic, Combined median and ulnar nerve palsy

**J Med Assoc Thai 2006; 89 (4): 533-40**

**Full text. e-Journal:** <http://www.medassocthai.org/journal>

---

The neuropathic arthropathy (Charcot joint) is a joint that lacks the ability to respond via reflexes to abnormal stress. Consequently, the subchondral bone of the involved joint disintegrates, leading to joint collapse and considerable joint deformity. Conventional radiography is the most commonly used imaging modality for diagnosing neuropathic arthropathy<sup>(1)</sup>. The disease is mostly of the hypertrophic type

and is manifested as soft-tissue swelling, subluxation, para-articular debris, osseous fragmentation and disorganization<sup>(2)</sup>.

The joints most frequently affected by Charcot pathology are the weight bearing joints, predominantly the mid foot but also the ankle, knee, hip and elbow. According to Johnson who had conducted a study of 118 cases with neuropathic arthropathy, the pattern of joint involvement was dependent upon the neurological condition. For example, in Tabes dorsalis, joint destruction was predominantly in the knee; in syringomyelia, joint destruction was predominant in the

---

Correspondence to : Unnanuntana A, Department of Orthopaedic Surgery, Faculty of Medicine, Siriraj Hospital, Mahidol University, Bangkok 10700, Thailand, Phone: 0-2411-3191, Fax: 0-2412-8172, E-mail: [uaasis@yahoo.com](mailto:uaasis@yahoo.com)

upper extremity; and in Diabetic neuropathy, foot and ankle destruction was predominant<sup>(3)</sup>.

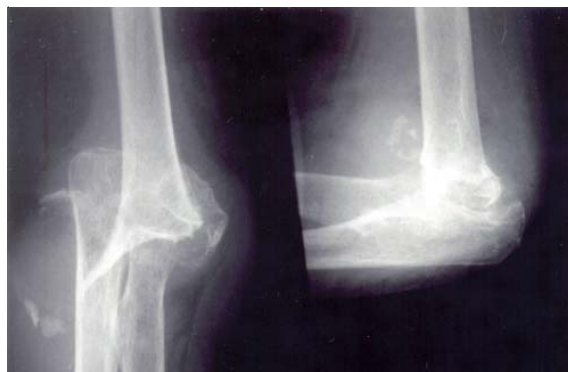The elbow is among the least frequently reported joints compromised by the charcot pathology. Generally, Tabes dorsalis and syringomyelia are the most common causes of neuropathic arthropathy of the elbow<sup>(4)</sup>. We retrospectively reviewed the records and radiographs of two patients with neuropathic arthropathy of the elbow. One of these two patients was presented with septic arthritis.

## Case Reports

### Case 1

A 66-year-old female came to our department with a five-day-long history of pain in her left elbow. She had a history of a fall to the ground on her left elbow 3 years ago but did not have any surgery or casting. She could use her left elbow as usual, seven days after the injury. Five days before coming to the hospital, while she was turning a doorknob, she felt pain at the medial aspect of her left elbow. The pain was minimal but persistent, so she came to the hospital. She had another two episodes of fracture. The first episode was about 30 years ago. The diagnosis was a fracture of right distal end radius that was treated by cast treatment for 6 weeks. It is now malunited without any clinical symptom. The other fracture was about two years ago. The diagnosis was a fracture of the medial epicondyle with marked displacement. She was treated at our department. While we planned to perform an operation, we had to change to a conservative treatment because of her past medical history. She was treated by placing on a long arm slab for three weeks and then early range of motion was permitted. There was no clinical symptom at her right elbow and she could perform her usual activities as before. She has had hypertension for 30 years and severe persistent asthma which was diagnosed about forty years ago, for which she has received medication regularly. She does not smoke or drink any alcoholic beverages. Review of other systems except the above was unremarkable.

On physical examination, the left elbow was deformed with minimal tenderness at the medial aspect. The range of motion was 140/0/25. There was gross instability of the left elbow shown in valgus and varus stress test. The motor power was grade V/V in both upper and lower extremities. The pinprick sensation and the joint positional sense were within normal limits. The deep tendon reflexes were normal. Other systems were examined and found to be within normal limits.



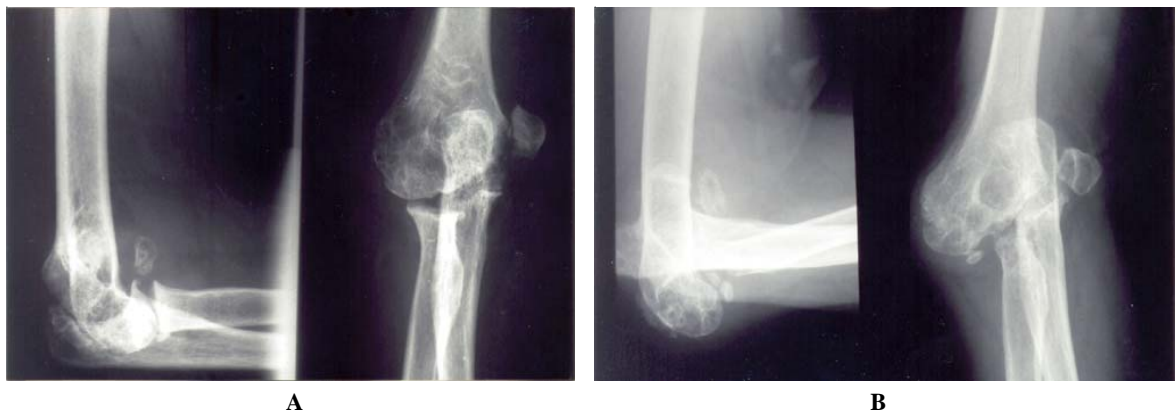**Fig. 1** Anteroposterior and lateral radiographs of the left elbow

Radiographs of the left elbow revealed a collapse of distal humeral articular surface and posteromedial subluxation of the elbow with bony fragments lying in the joint space and some heterotopic ossification in the adjacent tissues (Fig. 1). For the right elbow, comparing with the initial radiographs, the medial condyle collapsed superiorly and there was posterosuperior subluxation of the elbow with some bony fragments within the joint space (Fig. 2). According to the characteristic radiographic features, the preliminary diagnosis was neuropathic arthropathy of both elbows. However, there may be some other possibilities for this condition such as infection, crystal-induced arthritis or tumor. Therefore, synovial biopsy was performed in order to rule out those other possibilities. The biopsy did not reveal any pathogen, abnormal cell or any crystal. Therefore, the most likely diagnosis was neuropathic arthropathy. Some investigations, as shown in Table 1, were performed in order to find the underlying disease that associated with the neuropathic joint.

The patient was given a long-arm splint for seven days, and then range of motion exercises and other physical modalities were permitted. After removal of the splint, the patient did not have any swelling or discomfort. She still had 25-degree hyperextension of the elbow and 140-degree flexion. Although there was gross instability of the elbow, it was fully functional, and she regained the ability to perform her previous normal activities. An elbow brace was advised to provide some stability of the elbow; however, she chose not to use it.

### Case 2

A 63-year-old male came to see us two years ago with a four-day-long history of fever and mass at



**Fig. 2A, 2B** Anteroposterior and lateral radiographs of the right elbow at the initial injury and 2 years afterward

his left elbow. Seventeen years ago, he had had an electric shock and fell to the ground on his left elbow. He went to a hospital and he was given some pills. There was no fracture around the elbow. Since having suffered that injury, he has had a persistent numbness at the elbow and below. He first noticed a painless hard mass at his left elbow and went to see a physician at a hospital. The mass was excised without any complication. He could perform his daily activities as usual without any clinical symptom except for the persisting numbness at the elbow and below. Seven months before coming to our hospital, he fell to the ground on his left hand. He felt some discomfort at his

left elbow and noticed a mass at the lateral aspect of his left elbow. He went to the previous hospital and received a biopsy. The operative finding was old seroma with debris of cartilage. The pathologic result was chronic inflammation without any malignant cells. After the operation, the mass remained but there was no other symptom. He could still perform his routine work. Four days ago, he had a fever and the mass grew larger without any pain. He then came to our hospital. He has had diabetic mellitus and ischemic heart disease for 10 years and received medication regularly. Review of other systems was unremarkable.

**Table 1.** Laboratory studies and investigations in patient # 1

Hemoglobin	11.4 g/dl
Hematocrit	34.5%
White bloodcell count	6800/cumm
Polymorphs	47%
Lymphocytes	35%
Platelets	365000/cumm
ESR	55 mm/h
Glucose	93 mg/dl
BUN	22 mg/dl
Creatinine	1.1 mg/dl
Sodium	141 mmol/l
Potassium	4.4 mmol/l
Bicarbonate	28 mmol/l
Chloride	104 mmol/l
VDRL	non-reactive
EMG	no evidence of peripheral or nerveroot injury in both sides
MRI whole spine	no syringomyelia, generalized degenerative changes of the spine

On physical examination, there were fluctuant swelling and warmness at the medial aspect of the left elbow. Elbow flexion was from 0 to 120 degrees and forearm supination and pronation were 90 and 70 degrees respectively. The left elbow was marked unstable to varus and valgus stress test. Examination of the left hand revealed a decrease in light touch and discriminatory senses in the median and ulnar nerve distributions; weak intrinsic muscles; and grip strength of 12 kg while the right grip was 32 kg. The body temperature was 37.6 degrees Celsius, the white blood cell count was 15100/cumm with polymorphs 82% and the ESR was 99 mm/h. Radiographs revealed a collapsed distal humeral articular surface, posterior subluxation of the elbow with bone fragments in the joint space and heterotopic ossification in the surrounding soft tissues (Fig. 3). EMG revealed chronic inactive left median and ulnar nerve injuries. Arthrocentesis yielded mixed purulent and unclotted blood of which MSSA grew on culture.

The patient was treated by drainage through a medial incision and 100 ml of purulent fluid was removed from the joint. The articular surface of the

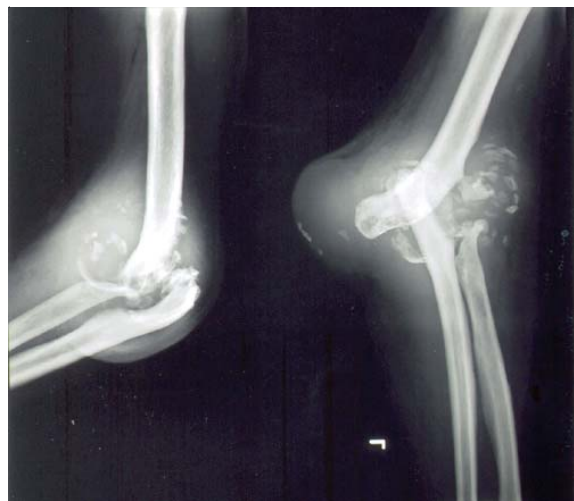distal humerus and proximal ulna and radius were destroyed. There were numerous fragments of bone and irregular pieces of rubbery grayish white tissue in the joint cavity. The joint was irrigated with normal saline solution and antiseptic solution. A rubber penrose drain was inserted into the joint cavity. The wound was then dressed and a posterior long arm slab was applied. The patient was given cloxacillin intravenously every day. Two weeks after the surgical procedure, there still was continuous serous discharge from the joint. The elbow was redebrided. An external fixator was applied from the humeral shaft to the shaft of ulna (Fig. 4), and the patient was given antibiotics intravenously for 4 weeks and orally thereafter. After the second operation, the swelling and inflammation at the elbow resolved rapidly. Four weeks after the operation, the patient was discharged from the hospital and was treated with antibiotics for six more weeks.

The external fixator was removed 13 weeks after the second operative procedure. The patient has been followed-up for two years and there have been no clinical or laboratory signs of infection and no recurrent drainage. On the most recent examination, he had no limitation of joint motion but some instability to valgus and varus stress test. Despite the instability of the joint, the function of the elbow was quite good.

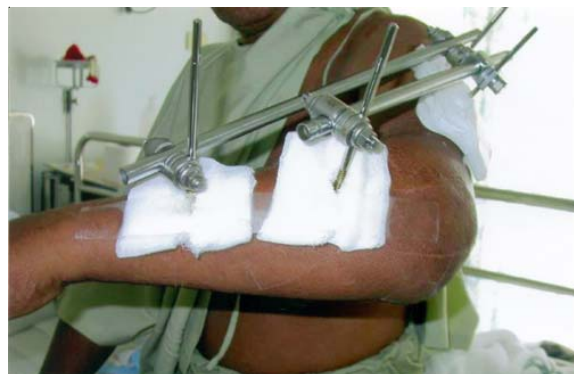
### Discussion

Neuropathic arthropathy of the elbow is a rare condition. From reviewing the literature, there are approximately 3-8% elbow neuropathic arthropathy out of all the cases of neuropathic joints<sup>(5,6)</sup>. Most of the documents reported only one or two cases except the study of Carl that reported five cases of neuropathic arthropathy of the elbow<sup>(4)</sup>. Although there is no unanimous agreement on the etiology and pathogenesis of the neuropathic joint, the current consensus supports the prominent role of misuse or abuse of insensitive joints in this condition. Loss of pain and proprioceptive sensations leads to relaxation of the soft tissue structures around the joints and this, in turn, leads to injury, malalignment and abnormal loading of the joints even with normal physiological loads of daily activities. Cumulative injury leads to progressive degeneration and disorganization of the articulation.

The pathologic and radiographic features of advanced neuropathic arthropathy are indeed characteristic, the "5Ds" which come from debris, density (sclerosis), destruction, disorganization and dislocation. The radiographic findings can be divided into



**Fig. 3** Anteroposterior and lateral radiographs of the left elbow showing marked destruction of the joints, osteophytes, and numerous loose bodies within the joint space



**Fig. 4** Picture of the left elbow, showing the joint immobilized by the external fixator. Pins transfixed in the humerus and ulnar shaft

two forms, hypertrophic or productive and atrophic or destructive. Hypertrophic changes are commonly associated with central spinal cord lesions such as trauma, tumor or congenital malformation whereas atrophic changes are associated with peripheral nerve injuries and are related to trauma, alcoholism and diabetes mellitus<sup>(4)</sup>. Some authors have emphasized the difference between these two forms of the diseases<sup>(5,8,9)</sup>; however, other authors have suggested that the hypertrophic and atrophic forms of neuropathic joints are only different stages in the natural progression of the disease<sup>(10)</sup>. Although the radiographic and pathologic features of this condition are generally similar in

**Table 2.** Common sites of involvement in neuropathic arthropathy<sup>(7)</sup>

Diseases	Sites of Involvement
Tabes dorsalis	Knee, hip, ankle, spine
Syringomyelia	Glenohumeral joint, elbow, wrist, spine
Diabetes mellitus	Metatarsophalangeal, tarsometatarsal, intertarsal joints
Alcoholism	Metatarsophalangeal, interphalangeal joints
Amyloidosis	Knee, ankle
Meningomyelocele	Ankle, intertarsal joints
Congenital sensory neuropathy, hereditary sensory radicular neuropathy	Knee, ankle, intertarsal, metatarsophalangeal, interphalangeal joints
Idiopathic	Elbow, shoulder

these various disorders, the distribution of the abnormalities varies among the disorders and can provide an important clue for a proper specific diagnosis as shown in Table 2. Specifically focused on neuropathic arthropathy of the elbow, a variety of diseases has been reported in the literature as shown in Table 3. Neuropathic arthropathy of the elbow is most often associated with syringomyelia and tabes dorsalis<sup>(4)</sup>.

Patients with a neuropathic joint may present with a joint effusion and may report a history of injury recently or in the distant past. Although it is classically described as painless lesion in neuropathic joint, one-third of the patients can have pain<sup>(5)</sup>. Our patient, the non-infected case, has neuropathic arthropathy of the elbow that was diagnostically shown in radiographic pictures. Although she was presented with mild pain at the medial aspect of the left elbow, there was no significant trauma in that area recently and she did not have any pain before. After a conservative treatment with rest, elevation and immobilization, the pain was resolved and she could return to her previous normal activities. She underwent many investigations in order to find the underlying disease that produced neuropathic arthropathy of the elbow, but there was no positive result. She had a history of trauma to both

**Table 3.** Some causes of neuropathic arthropathy of the elbow<sup>(4,11-14)</sup>

Syringomyelia
Tabes dorsalis
Peripheral neuropathy
Diabetes mellitus
Syringohydromyelia
Charcot-Marie-Tooth disease
Congenital insensitivity to pain
Systemic sclerosis
Surgical denervation
Idiopathic

elbows, the first time was three years ago at the left side, she was treated with immobilization for one week and the symptoms subsided. Therefore, we can imply from this history that the trauma was not severe enough to produce the features shown in the radiographs. For the right elbow that was diagnosed as medial epicondylar fracture 2 years ago, the recent radiographic picture differed from the previous radiographs, showing a bony pathology at that elbow. Therefore, the diagnosis in this patient is idiopathic neuropathic arthropathy of both elbows. In all cases, the treatment of neuropathic joint remain the same and is aimed at slowing down and minimizing the degree of joint pathology while retaining the function of the joint. The treatment can be divided into conservative and surgical treatment. Generally, surgery is considered only after all conservative measures have failed and the integrity of the soft tissue surrounding the joint is threatened. Additionally, surgery should be undertaken only when late stage of deformity is evident and conservative measures are inevitably useless<sup>(15)</sup>. Hatzis et al. reported successful treatment of mobilization instead of immobilization in neuropathic arthropathy of the shoulder<sup>(16)</sup>. From Carl et al. series, four out of five patients with neuropathic arthropathy of the elbow were successfully treated without immobilization of the elbow, but instead they were encouraged to use it<sup>(4)</sup>. Our patient was treated with immobilization only until the pain subsided.

Both of our patients (the non-infected case and the case that the infection was successfully treated) had instability of the elbow, but they demonstrated remarkable maintenance of functional elbow motion. In spite of continued subluxation, that is instability to varus and valgus, the patients were satisfied with their elbow function. This may be that the pain and apprehension, the usual symptoms associated with elbow instability, was masked by the underlying

**Table 4.** Summary of reported case of infected neuropathic joints with English-language literature

	No. of patients	Location	Etiology	Bacteria	Treatment
Martin, et al <sup>(17)</sup>	4	Knee	Tabes dorsalis	S. aureus	Surgical drainage and systemic antibiotics
Ward, et al <sup>(18)</sup>	1	Wrist	Syringomyelia	Pseudomonas arruginosa	Surgical drainage and systemic antibiotics
Rubinow, et al <sup>(19)</sup>	2	Shoulder	Syringomyelia	S.aureus	Multiple aspiration and systemic antibiotics
		Knee	Congenital insensitivity to pain	Beta-hemolytic streptococci	Surgical drainage and systemic antibiotics
Goodman, et al <sup>(20)</sup>	1	Shoulder	Congenital insensitivity to pain	S.aureus	Surgical drainage and systemic antibiotics but the patient turn to chronic osteomyelitis which needed 2 stage procedure of bone excision and the latissimus dorsi myocutaneous flap

disease. In addition, comparing to the natural history of neuropathic joint of lower extremities, the progress of the disease of elbow may stabilize and the elbow function maintained because of the lower loading force at the elbow.

Cases of septic arthritis complicating a neuropathic joint have been reported even less frequently and a review of pertinent literature revealed less than 10 cases in addition to those reported here. Table 4 summarizes the well-described cases of infected neuropathic joints in the English-language literature.

The diagnosis of joint infection in patients with neuropathic joints is difficult and needs careful surveillance as the usual clue of pain is lacking so that sepsis in a partially or totally anesthetized joint may be overlooked. Effusion can be missed in a distorted, hypertrophic joint. Thus, fever may be the only clue to alert the physician to become aware of this condition.

Successful treatment of patients with septic arthritis including those with infected neuropathic joints requires appropriate parenteral antibiotic therapy and drainage of the joint. The most common organisms found in the infected neuropathic joint are gram-positive cocci. Controversy still exists over the preferred method of initial drainage. Goldenberg et al<sup>(21)</sup> and Rubinow et al<sup>(19)</sup> suggested that repeated needle aspirations utilizing synovial fluid analysis as an indicator of therapeutic response is the initial treatment of choice. Surgical drainage is advised for loculated, grossly purulent parts of the joint. On the other hand, others advocated that initial operative treatment bring

about healing of the infectious process without subjecting the patient to multiple aspirations<sup>(22,23)</sup>. However, sometimes bacteria were resistant to antibiotic treatment even with appropriate surgical debridement, and amputation or wide resection may be needed<sup>(20)</sup>.

The authors suggest that infection in a neuropathic joint be drained initially by surgical drainage. The case received surgical drainage initially but immobilization method (posterior long arm slab) was not stable enough. After an external fixator had been placed, the infection resolved rapidly. From this information, the authors implied that in addition to surgical drainage and systemic antibiotic, an appropriate immobilization measure is needed while the infectious process is being healed.

### Conclusion

Neuropathic arthropathy of the elbow is a rare condition. If neuropathic arthropathy is found in the elbow as diagnosed from radiographic pictures, the underlying disease should be sought out. In case of septic arthritis, the treatment is difficult. In addition to systemic antibiotic and surgical debridement, appropriate immobilization during the healing process is necessary. The patients had gross instability of the elbow, they demonstrate remarkably good elbow function with non-operative treatment.

### References

1. Aliabadi P, Nikpoor N, Alparslan L. Imaging of neuropathic arthropathy. *Semin Musculoskelet*

- Radiol 2003; 7: 217-26.
2. Scott EK, Jordan BR, Andrew C. Infections, metabolic, and arthritic diseases of the musculoskeletal system. In: Diagnostic musculoskeletal surgical pathology: clinicoradiologic and cytologic correlations. Philadelphia: WB Saunders; 2004: 371-3.
  3. Johnson JTH. Neuropathic fractures and joint injuries. JBJS Am 1967; 49: 1-30.
  4. Carl AD, Sang-Gli PL, Jesse BJ. Neuropathic arthropathy of the elbow: a report of five cases. JBJS Am 2001; 6: 839-44.
  5. Brower AC, Allman RM. Pathogenesis of the neurotrophic joint: neurotraumatic and neurovascular. Radiology 1981; 139: 349-54.
  6. Floyd W, Lovell W, King R. The neuropathic joint. South Med J 1959; 52: 563-9.
  7. Resnick D. Neuropathic Osteoarthropathy. In: Resnick D, editor. Diagnostic of bone and joint disorders. 9<sup>th</sup> ed. Philadelphia: WB Saunders; 2002: 3564-95.
  8. Alpert SW, Koval KJ, Zuckerman JD. Neuropathic arthropathy: review of current knowledge. J Am Acad Orthop Surg 1996; 4: 100-8.
  9. Allman RM, Brower AC, Kotlyarov EB. Neuropathic bone and joint disease. Radiol Clin North Am 1988; 26: 1373-81.
  10. Koshino T. Stage classifications, types of joint destruction, and bone scintigraphy in Charcot joint disease. Bull Hosp Jt Dis Orthop Inst 1991; 51: 205-17.
  11. Nozawa S, Miyamoto K, Nishimoto H, Sakaguchi Y, Hosoe H, Shimizu K. Charcot joint in the elbow associated with syringomyelia. Orthopaedics 2003; 26: 731-2.
  12. Ecker J. Neuropathic joint changes in syringomyelia: problems in diagnosis and therapy based on a personal case. Z Orthop Ihre Grenzgeb 1983; 121: 288-91.
  13. Blanford AT, Keane SP, McCarty DJ, Albers JW. Idiopathic charcot joint of the elbow. Arthritis Rheum 1978; 21: 723-6.
  14. Meyn M Jr, Yablon IG. Idiopathic arthropathy of the elbow. Clin Orthop 1973; 97: 90-3.
  15. Gupta R. A short history of neuropathic arthropathy. Clin Orthop 1993; 296: 43-9.
  16. Hatzis N, Kaar TK, Wirth MA, Toro F, Rockwood CA Jr. Neuropathic arthropathy of the shoulder. JBJS Am 1998; 80: 1314-9.
  17. Martin JR, Root HS, Kim OS, Johnson LG. Staphylococcus suppurative arthritis occurring in neuropathic knee joints. Arthritis Rheum 1965; 8: 389.
  18. Ward J, Cohen AS, Bauer W. The diagnosis and therapy of acute suppurative arthritis. Arthritis Rheum 1960; 3: 522.
  19. Rubinow A, Spark EC, Canoso JJ. Septic arthritis in a charcot joint. Clin Orthop Relat Res 1980; 147: 203-6.
  20. Goodman MA, Swartz W. Infection in a charcot joint. JBJS 1985; 67: 642-3.
  21. Goldenberg DL, Brandt KD, Cohen AS, Cathcart ES. Treatment of septic arthritis: comparison of needle aspiration and surgery as initial modes of joint drainage. Arthritis Rheum 1975; 18: 83.
  22. Clawson DK, Dunn AW. Management of common bacterial infections of bones and joints. JBJS 1967; 49A: 164.
  23. Watkins MB, Samilson KL, Winters DM. Acute suppurative arthritis. JBJS 1956; 38A: 1313.

---

## รายงานผู้ป่วย 2 รายที่มีภาวะข้อศอกเสื่อมจากความผิดปกติของระบบประสาท

อาคิส อุณนะนนท์, สารเนตร ไวกกุล

**บทนำ:** ภาวะข้อเสื่อมสภาพจากความผิดปกติของระบบประสาทเป็นภาวะที่พบน้อย โดยจะเกิดกับข้อต่าง ๆ ในร่างกาย เช่นข้อเข่า, ข้อไหล่ เป็นต้น สำหรับข้อศอกจัดเป็นตำแหน่งที่พบความผิดปกติจากพยาธิสภาพนี้น้อยมาก โดยทั่วไปผู้ป่วยที่มีภาวะนี้จะมีอาการไม่มั่นคงของข้อนั้น ๆ มาก โดยที่ผู้ป่วยมีความเจ็บปวดน้อยหรือไม่เจ็บปวดเลย สำหรับการติดเชื้อในภาวะข้อเสื่อมสภาพจากความผิดปกติของระบบประสาทนี้พบน้อย มีรายงานจำนวนไม่มาก รายงานนี้ได้นำเสนอผู้ป่วย 2 รายซึ่งมีภาวะข้อศอกเสื่อมสภาพจากความผิดปกติของระบบประสาทและหนึ่งรายมีการติดเชื้อรวมด้วย

**วัสดุและวิธีการ:** ผู้ป่วย 2 รายที่ได้รับการวินิจฉัยว่าเป็นข้อศอกเสื่อมจากความผิดปกติของระบบประสาทได้ทำการรักษาที่โรงพยาบาลศิริราช ผู้ป่วยทั้ง 2 รายมีอายุมากกว่า 60 ปี โดยที่ผู้ป่วยรายหนึ่งได้รับการวินิจฉัยว่าเป็นข้ออักเสบติดเชื้อพบว่ามีพยาธิสภาพของเส้นประสาท median กับ ulnar มากอน ส่วนอีกรายหลังจากตรวจค้นเพิ่มเติมแล้วไม่พบสาเหตุที่ทำให้เกิดพยาธิสภาพดังกล่าว แม้ว่าจะมีประวัติอุบัติเหตุกับข้อศอกนั้นมาก่อนก็ตาม ผู้ป่วยทั้ง 2 รายมีลักษณะภาพถ่ายรังสีจำเพาะต่อภาวะข้อเสื่อมจากความผิดปกติของระบบประสาท ได้แก่ ผิวของข้อเคลื่อนหลุดจากกัน หัวกระดูกที่ประกอบกันเป็นข้อต่อถูกทำลายเสียหายเห็นเป็นเศษกระดูกกระจายอยู่รอบ ๆ ข้อ ได้ทำการรักษาด้วยวิธีอนุรักษนิยมในผู้ป่วยที่ไม่มีข้ออักเสบติดเชื้อ โดยการใส่เฝือกอ่อนเป็นระยะเวลาสั้น ๆ จากนั้นเริ่มให้เคลื่อนไหวข้อศอกได้ ร่วมกับการบริหารกล้ามเนื้อบริเวณรอบ ๆ สำหรับผู้ป่วยที่มีข้ออักเสบติดเชื้อนั้นได้ทำการรักษาโดยผ่าตัดล้างผิวข้อ ร่วมกับการให้ยาปฏิชีวนะและการใส่เหล็กยึดตรึงกระดูกภายนอกเพื่อให้ข้ออยู่นิ่งเป็นระยะเวลาหนึ่ง

**ผลการศึกษา:** ผู้ป่วยได้รับการติดตามหลังการรักษาเป็นระยะเวลานาน 9 เดือนสำหรับรายที่ไม่มีการติดเชื้อ และ 2 ปีในรายที่มีการติดเชื้อ ผู้ป่วยทั้ง 2 รายไม่มีอาการปวดที่บริเวณข้อศอกที่มีพยาธิสภาพและสามารถใช้งานข้อศอกนั้น ๆ ในการทำกิจวัตรประจำวันได้ แม้ว่าผู้ป่วยทั้งคู่จะยังมีอาการแสดงของข้อไม่มั่นคงอยู่ก็ตาม

**สรุป:** ภาวะข้อศอกเสื่อมจากความผิดปกติของระบบประสาทเป็นภาวะที่พบน้อย ผู้ป่วยทั้งสองรายมีอาการ อาการแสดง และพบในภาพถ่ายรังสีร่วมกับได้ทำการตรวจค้นเพิ่มเติมเพื่อหาสาเหตุของพยาธิสภาพดังกล่าว และให้การรักษาแบบอนุรักษนิยม แม้ว่าผู้ป่วยจะยังคงมีความไม่มั่นคงของข้อเหลืออยู่ แต่ผู้ป่วยทั้งสองก็สามารถใช้งานข้อต่ออื่น ๆ ได้ สำหรับผู้ป่วยที่มีการติดเชื้อในข้อได้รับการรักษาด้วยการผ่าตัดล้างผิวข้อ การให้ยาปฏิชีวนะ และการดามข้อต่ออื่นเป็นระยะเวลาหนึ่ง

---