

## Case Report

# Infective Endocarditis in Hypertrophic Cardiomyopathy - Mural and Aortic Valve Vegetations: A Case Report

Orathai Pachirat MD\*,  
Virat Klungboonkrong MD, FACC\*, Cherdchai Tantisirin MD\*

\* Division of Cardiovascular Disease, Department of Medicine, Faculty of Medicine,  
Khon Kaen University, Khon Kaen

*Hypertrophic cardiomyopathy (HCM) is infrequently complicated by infective endocarditis (IE). The authors report the case of a 46-year-old woman developing IE in asymptomatic HCM. Blood cultures were positive for Streptococcus viridans. Echocardiography demonstrated: 1) a mobile (1.2 x 1 cm<sup>2</sup>) vegetation attached to the septal endocardium at the site of contact between the mitral valve leaflet and the hypertrophic septum; 2) two large (2.7 x 1.7 cm<sup>2</sup> and 1.6 x 1.1 cm<sup>2</sup>) vegetations at NCC and RCC respectively of aortic valve, causing moderate valve regurgitation; and, 3) a mural (1 x 0.8 cm<sup>2</sup>) vegetation on the posterior wall of the left ventricle. On the third day of hospitalization, the patient underwent aortic valve replacement and removal of the vegetations. Antibiotics were continued for another four weeks. The patient recovered and follow-up was uneventful. Thus, chronic endocardial trauma of the septum, a common finding in HCM with outflow tract obstruction, may provide a fertile nidus for the development of vegetation, which in turn would play the major role in the pathogenesis of IE.*

**Keywords:** Hypertrophic cardiomyopathy, Infective endocarditis, Streptococcus viridans

**J Med Assoc Thai 2006; 89 (4): 522-6**

**Full text. e-Journal:** <http://www.medassocthai.org/journal>

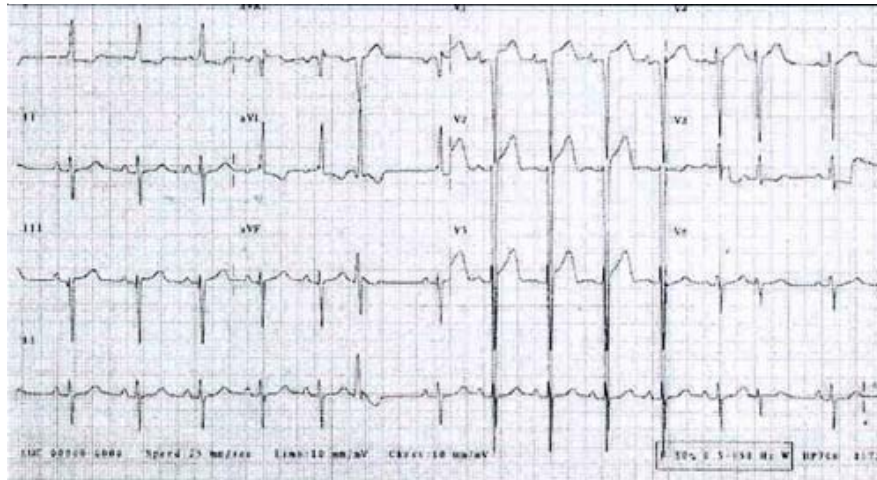
Infective endocarditis (IE) complicating hypertrophic cardiomyopathy (HCM) is not commonly reported but occurs almost universally in patients showing evidence of outflow tract obstruction. The estimated cumulative 10-year probability of developing IE in obstructive HCM is < 5%<sup>(1)</sup> Since there are few reports on the pathological observations of IE complicating HCM, the authors report a case of community-acquired Streptococcus viridans, aortic valve and mural vegetations endocarditis in a woman with previously asymptomatic HCM and a modest basal outflow tract gradient. The authors describe the HCM with moderate aortic regurgitation (AR) and mural vegetations resulting from IE, and we review the relevant literature.

Correspondence to : Pachirat O, Cardiovascular Disease Division, Department of Medicine, Faculty of Medicine, Khon Kaen University, Khon Kaen 40002, Thailand. E-mail: Orathai@hotmail.com

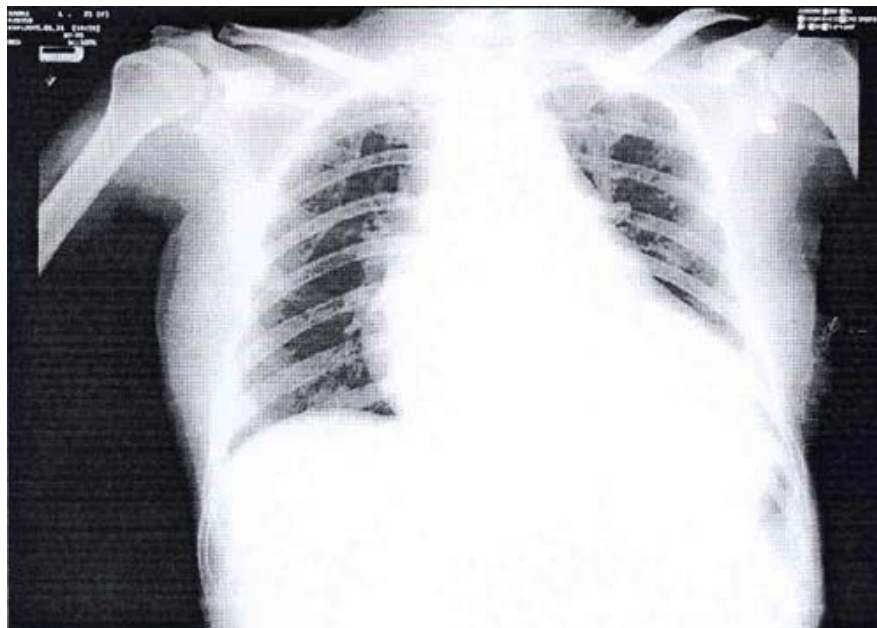
### Case Report

A 46-year-old woman was transferred for management of IE, after the diagnosis of IE was made at the referring hospital. On admission to our hospital, her vital signs included: temperature (39°C), pulse (100/min) and blood pressure (110/80 mmHg).

Her physical examination showed a grade 3/6 harsh systolic murmur along the left parasternal border but no rales on the lung fields. The electrocardiogram showed sinus rhythm, left axis deviation, frequent premature atrial contractions and left ventricular hypertrophy (Fig. 1). Moderate cardiomegaly was revealed on the chest roentgenogram (Fig. 2). Transthoracic echocardiography demonstrated a septal hypertrophy (3.2 cm) with systolic anterior motion of the anterior mitral leaflet (SAM) and a moderate outflow tract obstruction (mean pressure gradient 45 mmHg). There were multiple vegetations: 1) two large (2.7 x 1.7 cm<sup>2</sup> and 1.6 x 1.1 cm<sup>2</sup>) vegetations on NCC and RCC respectively of the aortic valve causing moderate AR; 2) a mobile (1.2 x 1 cm<sup>2</sup>) vegetation attached to the septum



**Fig. 1** ECG showed normal sinus rhythm, left axis deviation, frequent premature atrial contraction and left ventricular hypertrophy



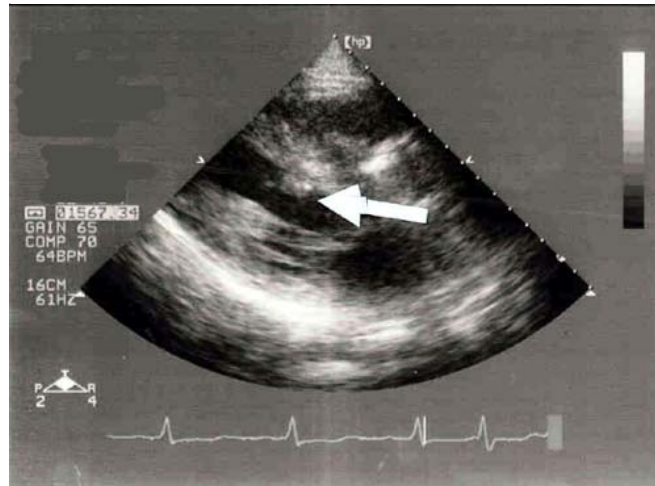
**Fig. 2** Chest x-ray showed cardiomegaly

(where mitral-septal contact occurred during systole); and, 3) a mural ( $1 \times 0.8 \text{ cm}^2$ ) vegetation on the posterior wall of left ventricle opposite site of septal vegetation (kissing lesion) (Fig. 3-5).

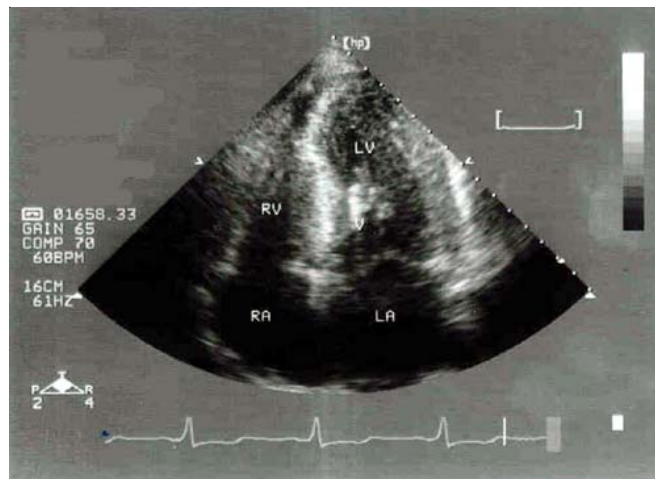
Following diagnosis of *Streptococcal viridans* IE, the patient was placed on intravenous third generation cephalosporin and the case was discussed with a cardiothoracic surgeon. The patient underwent early surgical replacement of the aortic valve and removal of vegetations on the third day of hospitalization.

***Surgical findings and clinical course***

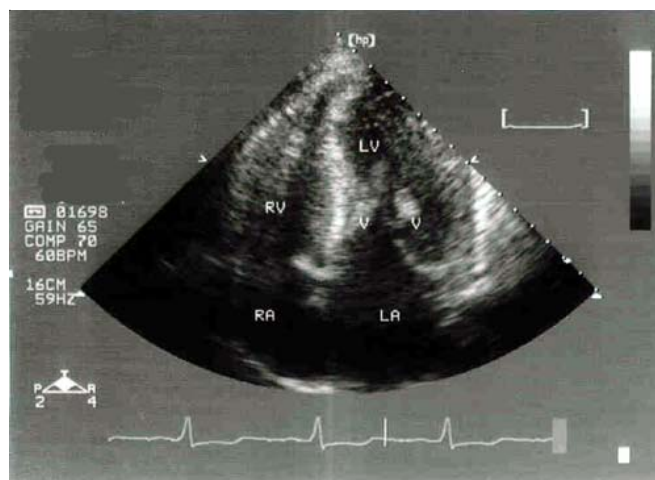
The diagnosis of HCM was confirmed during surgery with visualization of hypertrophy of the left ventricle, especially at the interventricular septum. Vegetations were attached to the interventricular septum in the area of chronic endocardial trauma of the left ventricular outflow tract and one opposite on the posterior wall of the left ventricle. Vegetations were also seen on the NCC and RCC of aortic valve. Aortic valve replacement and removal of vegetations were



**Fig. 3** Echocardiography. Arrow mark vegetations attached to the hypertrophic septum



**Fig. 4** Echocardiography showed vegetation attached to the hypertrophic septum ( mural vegetation )



**Fig 5.** Echocardiography showed vegetations attached to the hypertrophic septum and the posterior wall of left ventricle

performed. The authors did not performed myomec-tomy of the hypertrophic septum because there was no severe outflow tract obstruction. One month after the combined surgery and antibiotic therapy, the patient was doing well and was asymptomatic.

### Discussion

Infective endocarditis in HCM is an uncommon complication and usually associated with increased morbidity and mortality<sup>(10-12)</sup>. During the last 20 years, only 33 cases of IE complicated HCM were published<sup>(1)</sup>. The real frequency of IE in the overall HCM population likely remains unknown.

The literature indicates IE can involve the aortic or mitral valve, or both<sup>(2-6)</sup>, the chordae tendineae<sup>(7)</sup> or the subaortic interventricular septum<sup>(8,9)</sup>; the pathogenesis of infective vegetations has not been completely clarified and understanding this would be helpful. It is clear from morphological studies that systolic anterior motion of the anterior motion leaflet is relevant to the pathogenesis of endocarditis<sup>(3)</sup>. In the most comprehensive study of prevalence and incidence, by Spirito et al<sup>(1)</sup>, identified 10 patients with HCM and endocarditis, outflow tract obstruction and atrial dilatation present in all cases.

A pathological investigation by Le Jemtel et al<sup>(7)</sup> revealed evidence of an endocardial plaque in the left ventricular outflow tract, with thickening of the mitral valve and the presence of disorganized septal muscle bundles. Although the anterior leaflet of the mitral valve was abnormally deformed, it appeared that the major area of friction was between the anterior leaflet (which apparently had fused and thickened chordae) and the septal outflow tract. This localization suggested that chronic endocardial trauma occurred by mitral-septal contact during systole and subsequently causing an area of thickened mural endocardium.

What makes the presented case unusual is the demonstration of chronic endocardial trauma arising from the septal opposition of the mitral valve during systole, which is a typical feature of hypertrophic obstructive cardiomyopathy, which may be an initial site or location of the development of infective vegetations and the posterior wall of the left ventricle (kissing lesion).

### Clinical Implications

It is well known that patients with HCM are at risk for the development of IE. Based on the authors' observations and the literature reviewed, antibiotic

prophylaxis for IE really is necessary but only in patients with outflow tract obstruction. It is recommended that in patients with HCM and cause-unknown prolonged fever, IE should be included in the differential diagnosis.

### Conclusion

The incidence of infective endocarditis in HCM with left ventricular outflow tract obstruction is almost the same as that for valvular heart diseases. The vegetations can be found on the anterior mitral leaflet, aortic cusps and mural subaortic endocardium and the posterior wall of the left ventricle. Chronic endocardial trauma caused by persistent friction between anterior mitral leaflet and septal outflow tract may provide a fertile nidus and play a major role for vegetative pathogenesis.

### Acknowledgments

The authors wish to thank the Faculty of Medicine, Khon Kaen University for financial and moral support and Mr. Bryan Roderick Hamman for his assistance with the English-language presentation.

### References

1. Spirito P, Rapezzi C, Bellone P, Betocchi S, Autore C, Conte MR, et al. Infective endocarditis in hypertrophic cardiomyopathy: prevalence, incidence, and indications for antibiotic prophylaxis. *Circulation* 1999; 99: 2132-7.
2. Frank S, Braunwald E. Idiopathic hypertrophic subaortic stenosis. Clinical analysis of 126 patients with emphasis on natural history. *Circulation* 1968; 37: 759-88.
3. Roberts WC, Kishel JC, McIntosh CL, Cannon RO III, Maron BJ. Severe mitral and aortic regurgitation or both, requiring valve replacement for infective endocarditis complicating hypertrophic cardiomyopathy. *J Am Coll Cardiol* 1992; 19: 365-71.
4. Ninomiya M, Takamoto S, Kotsuka Y, Ohtsuka T, Ueno K. Hypertrophic obstructive cardiomyopathy associated with mitral regurgitation due to infective endocarditis. *Jpn J Thorac Cardiovasc Surg* 2000; 48: 820-3.
5. Alessandri N, Pannarale G, del Monte F, Moretti F, Marino B, Reale A. Hypertrophic obstructive cardiomyopathy and infective endocarditis: a report of seven cases and a review of the literature. *Eur Heart J* 1990; 11: 1041-8.
6. Spirito P, Seidman CE, McKenna WJ, Maron BJ.

- The management of hypertrophic cardiomyopathy. *N Engl J Med* 1997; 336: 775-85.
7. LeJemtel TH, Factor SM, Koenigsberg M, O'Reilly M, Frater R, Sonnenblick EH. Mural vegetations at the site of endocardial trauma in infective endocarditis complicating idiopathic hypertrophic subaortic stenosis. *Am J Cardiol* 1979; 44: 569-74.
  8. Wang K, Gobel FL, Gleason DF. Bacterial endocarditis in idiopathic hypertrophic subaortic stenosis. *Am Heart J* 1975; 89: 359-65.
  9. Chagnae A, Rudniki C, Loebel H, Zahavi I. Infectious endocarditis in idiopathic hypertrophic subaortic stenosis: report of three cases and review of the literature. *Chest* 1982; 81: 346-9.
  10. Pollick C, Rakowski H, Wigle ED. Muscular subaortic stenosis: the quantitative relationship between systolic anterior motion and the pressure gradient. *Circulation* 1984; 69: 43-9.
  11. Robbins N, Szilagyi G, Tanowitz HB, Luftschein S, Baum SG. Infective endocarditis caused by *Streptococcus mutans*. A complication of idiopathic hypertrophic subaortic stenosis. *Arch Intern Med* 1977; 137: 1171-4.
  12. Oakley CM, Hall RJ. Endocarditis: problems - patients being treated for endocarditis and not doing well. *Heart* 2001; 85: 470-4.

---

## โรคเยื่อหัวใจติดเชื้อในผู้ป่วยกล้ามเนื้อหัวใจหนา

อรทัย พาชีรัตน์, วิรัตน์ คลังบุญครอง, เชิดชัย ตันติศิรินทร์

ผู้ป่วยหญิง อายุ 46 ปี ถูกส่งตัวมารับการรักษาต่อที่โรงพยาบาลศรีนครินทร์ ด้วยโรคเยื่อหัวใจติดเชื้อในผู้ป่วยกล้ามเนื้อหัวใจหนา เพราะเชื้อในเลือดได้เชื้อ *Streptococcus viridans* จากการตรวจด้วย echocardiogram พบว่า มี vegetations หลายตำแหน่ง ทั้งที่ลิ้นเอออร์ติกและผนังหัวใจ ได้ทำการผ่าตัดเปลี่ยนลิ้นหัวใจ aortic และตัด vegetation ทั้งหมดออก ผู้ป่วยมีอาการปกติดีหลังได้รับการรักษา จากรายงานฉบับนี้แพทย์ผู้ดูแลควรคำนึงถึงการป้องกันโรคเยื่อหัวใจติดเชื้อในผู้ป่วยกล้ามเนื้อหัวใจหนา โดยเฉพาะกลุ่มที่มีการปิดกั้นทางเดินเลือด และควรคำนึงถึงโรคนี้ เมื่อผู้ป่วยมาด้วยอาการไขเรื้อรังที่ไม่ทราบสาเหตุ