

Case Report

A Rare Case of Chylous Ascites and Chyluria in an Adult Nephrotic Syndrome with Focal Segmental Glomerulosclerosis

Songkiat Lewsuwan MD*,
Talerngsak Kanjanabuch MD*, Yingyos Avihingsanon MD*,
Kearkiat Praditpornsilpa MD*, Somchai Eiam-Ong MD*

* Division of Nephrology, Department of Medicine, Faculty of Medicine, Chulalongkorn University Hospital

The authors report the first case of chylous ascites and chyluria in a 65-year-old Thai woman with nephrotic syndrome due to focal segmental glomerulosclerosis (FSGS), tip variant. She presented with generalized edema and abdominal discomfort. Abdominal paracentesis revealed milky white fluid. Chylous ascites was confirmed. Abdominal and thoracic computed tomography did not show any cause of chylous ascites and chyluria. Lymphoscintigraphy could not demonstrate lymph flow obstruction and connection between lymphatic pathway and KUB system. Those could have explained the chylous ascites or chyluria. Hypoalbuminemia-induced bowel edema may predispose to change the permeability of mucosal or serosal lymphatics. This could result in chylous ascites but the cause of chyluria could not be determined in this case.

Keywords: Chylous ascites, Chyluria, Nephrotic syndrome, FSGS

J Med Assoc Thai 2006; 89 (Suppl 2): S253-6

Full text. e-Journal: <http://www.medassochai.org/journal>

Chylous ascites is defined as the extravasation of milky or creamy peritoneal fluid into the abdominal cavity. This fluid is rich in triglycerides and is caused by the leakage of thoracic or intestinal lymph. Chylous ascites is rare, with an incidence of approximately 1 in 20,500 patients⁽¹⁾. The major causes are hereditary, post-operation, trauma, cirrhosis, malignancies (lymphoma), and infectious diseases (tuberculosis and filariasis). Lindenbaum and Scheidt reported the existence of chylous ascites in patients with nephrotic syndrome in 1968⁽²⁾. They reviewed 140 cases of nephrotic syndrome and found that 90 patients had ascites and 35 of those underwent paracentesis. Only 2 adults and 14 children had "chylous ascites". However, the triglyceride levels in ascites were not measured. To the authors' knowledge, chylous ascites is rarely reported in adult nephrotic patients⁽³⁻⁷⁾ and true pathogenesis remains to be determined. The patho-

logic findings in their patients were membranous nephropathy (2 patients)^(3,6), membranoproliferative glomerulonephritis (1 patient)⁽⁷⁾ and focal segmental glomerulosclerosis (2 patients)^(4,5). No one has ever reported the existence of chylous urine and nephrotic syndrome. Gluck Z et al reported 5 cases of nephrotic syndrome with chyluria, however, the coexistence of nephrotic syndrome and chyluria were thought coincidentally due to congenital lymphatic abnormalities. The authors herein first reported the coexistence of chylous ascites and chyluria in an elderly patient who presented with nephrotic syndrome due to focal segmental glomerulosclerosis (FSGS).

Case Report

A 65-year-old Thai female was referred to King Chulalongkorn Memorial Hospital because of generalized edema and white urine for the last month. Later she developed progressive dyspnea and edema and her urine was reduced. She had been treated for tuberculosis at 45 years old and had pelvic surgery due to pelvic relaxation at 55 years old. Physical examination revealed

Correspondence to : Kanjanabuch T, Division of Nephrology, Department of Medicine, Faculty of Medicine, Chulalongkorn University Hospital, Bangkok 10330, Thailand. Phone: 0-2256-4321, Fax: 0-2252-6920, E-mail: golfnephro@hotmail.com

a chronically ill appearance and presence of pitting edema in the lower extremities. Her blood pressure was 130/76 mmHg, and body weight was 55 kg. Chest and cardiovascular examinations were normal. Abdominal examination revealed soft, no hepatosplenomegaly but positive shifting dullness. No signs of chronic liver stigmata and lymphadenopathy were present. Laboratory examination revealed blood urea nitrogen of 96 mg/dl, a serum creatinine of 1.5 mg/dl and 8.28 g/day proteinuria. Her serum albumin was 1.4 g/dl, blood sugar was 113 mg/dl, cholesterol was 490 mg/dl and triglyceride was 425 mg/dl. A complete blood count revealed hemoglobin of 10.6 g/dl, WBC of 9180/ μ l and platelet count of 326,000/ μ l. Her liver function test was normal. Her urine was milky white and disclosed 20-30 RBC/high power field and 2-3 WBC/high power field. ANA, anti HIV, viral hepatitis profiles, ANCA, cryoglobulin, ASO and anti-DNase B were negative. Complement and serum protein electrophoresis were normal. KUB ultrasonography revealed both normal kidney sizes and moderate ascites. Kidney biopsy was performed and the pathology of her nephrotic syndrome revealed focal segmental glomerulosclerosis, tip variant (Fig. 1). After 60 mg/day prednisolone was started with 20-40 mg/day furosemide, both her edematous legs were improved. 10 mg/day simvastatin was used to control hypercholesterolemia.

About 1 week after discharge from hospital, she was re-admitted due to progressive abdominal discomfort. Physical examination revealed marked

abdominal distension and positive shifting dullness. Abdominal paracentesis was performed and disclosed a moderate milky white fluid (Fig. 2). Ascitic examination revealed negative for cytology, fat stain using Oil-Red-O, PCR for *M. tuberculosis* and culture. Cholesterol, triglyceride, and albumin level in serum, urine, and ascites are shown in Table 1.

Abdominal computed tomography revealed massive ascites but no lymphadenopathy or organomegaly and thoracic computed tomography revealed fibrocalcific opacity, atelectasis and bronchiectatic change in posterior segment of RUL. Minimal fibrosis at apicoposterior segment of LUL and minimal opacity in superior lingular segment. No pleural effusion was present. Lymphoscintigraphy by Tc-99m dextran was performed and demonstrated no evidence of lymphatic obstruction and leakage.

After partial parenteral nutrition and a low fat diet was administered and multiple abdominal paracenteses were performed for ascitic reduction, her clinical condition was improved and ascites was reduced and were less turbid until she was discharged.

Discussion

Triglyceride levels in chylous ascites are typically above 200 mg/dl, although some authors use a cut-off value of 110 mg/dl⁽¹⁾. One report suggested that a ratio of triglyceride to cholesterol values in ascites may be a good indicator for the diagnosis of chylous ascites, especially if the ratio is more than 7.0, because

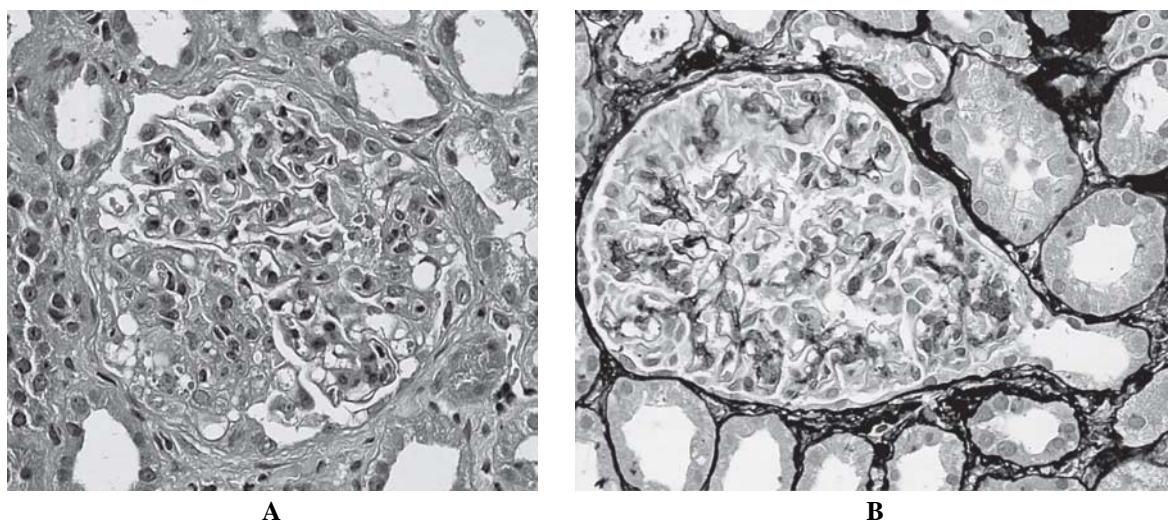


Fig. 1 The kidney pathology revealed focal segmental glomerulosclerosis. The left glomerulus shows segmental endocapillary proliferation of foam cells (A). The right one shows glomerular tip lesion (B)



Fig. 2 Milky white peritoneal fluid

Table 1. Chemistries of serum and ascites

| | Albumin (g/dl) | Cholesterol (mg/dl) | Triglyceride (mg/dl) |
|---------|----------------|---------------------|----------------------|
| Serum | 1.5 | 284 | 175 |
| Ascites | 0.1 | 8 | 178 |
| Urine | 0.1 | 8 | 178 |

triglyceride levels in chylous ascites varied from 90-529 mg/dl⁽³⁾. In the presented patient, the ratios of triglyceride to cholesterol values in ascites from 2 abdominal paracenteses were 17.15 (223/13) and 22.25 (178/8), respectively, though triglyceride level in ascites of one paracentesis was below 200 mg/dl. In contrast, triglyceride level is more than 200 mg/dl, but high cholesterol level may be pseudo-chylous fluid due to cholesterol or lecithin-globulin compounds.

Chyluria is rarely reported in adult nephrotic syndrome, too. The most common cause of chyluria is filariasis. Some reports presented cases of nephrotic syndrome with chyluria⁽⁸⁻¹⁰⁾ but most of these cases could demonstrate connection between lymphatic pathway and KUB system. The authors performed a kidney biopsy to confirm definite diagnosis of nephrotic syndrome but failed to demonstrate abnormal pathologic

findings and finally concluded that chyluria was the cause of nephrotic syndrome.

The presented patient could not demonstrate the cause of lymph flow obstruction and connection between lymphatic pathway and KUB system. Also, the authors could demonstrate focal segmental glomerulosclerosis from kidney biopsy that resulted in nephrotic syndrome in the presented case. Hypoalbuminemia-induced bowel edema may predispose to change the permeability of mucosal or serosal lymphatics⁽²⁾. This could result in the leakage of chylomicrons in peritoneal cavity and chylous ascites. But the cause of chyluria in the presented case could not be determined because of no connection between lymphatic pathway and the KUB system and the serum triglyceride was not high enough. This is the third case of focal segmental glomerulosclerosis who presented chylous ascites

but the first report of chyluria and chylous ascites in adult nephrotic syndrome.

Conclusion

Chylous ascites and chyluria in the setting of nephrotic syndrome is an extremely rare event. Nevertheless, when a patient has chylous ascites and chyluria, nephrotic syndrome should be included in the differential diagnosis.

References

1. Press OW, Press NO, Kaufman SD. Evaluation and management of chylous ascites. *Ann Intern Med* 1982;96: 358-64.
2. Lindenbaum J, Scheidt SS. Chylous ascites and the nephrotic syndrome. Report of a case, associated with renal vein thrombosis. *Am J Med* 1968; 44: 830-6.
3. Kato A, Kohno S, Ohtake T, Takita T, Hirshida A. Chylous ascites in an adult patient with nephrotic syndrome due to membranous nephropathy. *Nephron* 2001; 89: 361-2.
4. Moss R, Hinds S, Fedullo AJ. Chylothorax: a complication of the nephrotic syndrome. *Am Rev Respir Dis* 1989; 140: 1436-7.
5. Voudiclaris S, Sonikian M, Kallivretakis N, Pani I,

Kakavas I, Papageorgiou K. Chylothorax and nephrotic syndrome. *Nephron* 1994; 68: 388.

6. Lin SH, Lin YF, Shih YL. An unusual complication of nephrotic syndrome: chylothorax treated with hemodialysis. *Nephron* 2001; 87: 188-9.
7. Chen YC, Kuo MC, Chen HC, Liu MQ, Hwang SJ. Chylous ascites and chylothorax due to the existence of transdiaphragmatic shunting in an adult with nephrotic syndrome. *Nephrol Dial Transplant* 2005; 20: 1501-2.
8. Suzuki R, Morita H, Sugeno Y, Mizobuchi M, Yamamoto W, Ideura T, et al. A case report of chronic chyluria probably due to Bancroftian filariasis, which showed hypoproteinemia. *Nippon Jinzo Gakkai Shi* 2001; 43: 63-8.
9. Gluck Z, Ruegger S, Sulser T. A rare cause of nephrotic syndrome in a young woman with flank pain, milky urine and leukocyturia. *Ther Umsch* 2002; 59: 144-7.
10. Kano K, Arisaka O. Chyluria due to retroperitoneal lymphangioma producing nephrotic syndrome. *J Pediatr* 2003; 143: 685.
11. Gluck Z, Ruegger S, Sulser T. A rare cause of nephrotic syndrome in a young woman with flank pain, milky urine and leukocyturia. *Ther Umsch* 2002; 59: 144-7.

รายงานผู้ป่วยเนฟโฟรติกที่มาด้วยอาการท้องโตจากการสะสมของน้ำเหลืองในช่องท้อง

ทรงเกียรติ หลิวสุวรรณ, เถลิงศักดิ์ กาญจนบุษย์, ยิงยศ อวิหิงสานนท์, เกื้อเกียรติ ประดิษฐ์พรศิลป์, สมชาย เอี่ยมอ่อง

รายงานผู้ป่วยรายแรกของโลกที่มาด้วย chylous ascites และ chyluria ในผู้ป่วยเนฟโฟรติก ผู้ป่วยรายนี้ อายุ 65 ปี ได้รับการวินิจฉัยเป็น focal segmental glomerulosclerosis ชนิด tip variant มาพบแพทย์ด้วยอาการท้องโตขึ้น และปัสสาวะมีสีขาวขุ่น แพทย์ได้ทำการเจาะท้องซึ่งต่อมาพบว่าน้ำในช่องท้องมีสีขาวขุ่นเช่นกันและผลทางห้องปฏิบัติการยืนยันว่าเป็นส่วนประกอบของน้ำเหลืองเนื่องจากมีระดับไตรกลีเซอไรด์ที่สูง ผลเอกซเรย์คอมพิวเตอร์ทางช่องท้องและช่องอกไม่พบความผิดปกติที่อธิบายปรากฏการณ์ดังกล่าวรวมถึงการทำเอกซเรย์นิวเคลียร์ทางหลอดน้ำเหลืองไม่พบการอุดตันของทางเดินน้ำเหลืองและการเชื่อมต่อกันของทางเดินน้ำเหลืองกับระบบทางเดินปัสสาวะผนังลำไส้บวมจากภาวะอัลบูมินในเลือดต่ำของผู้ป่วยเนฟโฟรติกอาจอธิบายการรั่วของน้ำเหลืองที่ผนังลำไส้ได้ แต่ไม่สามารถอธิบายสาเหตุของน้ำเหลืองในปัสสาวะของผู้ป่วยรายนี้ได้