

## CASE REPORT

# NOCARDIA BEIJINGENSIS PSOAS ABSCESS AND SUBCUTANEOUS PHAEOHYPHOMYCOSIS CAUSED BY PHAEOACREMONIUM PARASITICUM IN A RENAL TRANSPLANT RECIPIENT: THE FIRST CASE REPORT IN THAILAND

Nattawan Palavutitotai<sup>1</sup>, Piriyaoporn Chongtrakool<sup>2</sup>, Popchai Ngamskulrungrroj<sup>2</sup>  
and Methee Chayakulkeeree<sup>1</sup>

<sup>1</sup>Division of Infectious Diseases and Tropical Medicine, Department of Medicine,

<sup>2</sup>Department of Microbiology, Faculty of Medicine Siriraj Hospital,  
Mahidol University, Bangkok, Thailand

**Abstract.** We describe the first case of a psoas muscle abscess caused by *Nocardia beijingensis* and subcutaneous phaeohyphomycosis caused by *Phaeoacremonium parasiticum* in a renal transplant recipient. The patient was treated for nocardiosis with percutaneous drainage and intravenous trimethoprim/sulfamethoxazole (TMP/SMX) combined with imipenem for 2 weeks, followed by a 4-week course of intravenous TMP/SMX and then oral TMP/SMX. During hospitalization for the psoas muscle abscess the patient developed cellulitis with subcutaneous nodules of his right leg. Skin biopsy and cultures revealed a dematiaceous mold, subsequently identified as *P. parasiticum* by DNA sequencing. The subcutaneous phaeohyphomycosis was treated with surgical drainage and liposomal amphotericin B for 4 weeks followed by a combination of itraconazole and terbinafine. The patient gradually improved and was discharged home after 18 weeks of hospitalization.

**Keywords:** *Nocardia*, nocardiosis, psoas abscess, dematiaceous fungi, phaeohyphomycosis, kidney transplant

### INTRODUCTION

Nocardiosis is a rare, life-threatening opportunistic infection that can occur in immunocompromised patients, such as

---

Correspondence: Dr Methee Chayakulkeeree, Division of Infectious Disease and Tropical Medicine, Department of Medicine, Faculty of Medicine Siriraj Hospital, Mahidol University, Bangkok 10700, Thailand.

Tel: +66 (0) 2419 9462; Fax: +66 (0) 2419 7783

E-mail: methee.cha@mahidol.ac.th

renal transplant recipients (Clark, 2009; Lebeaux *et al*, 2014). The main route of infection is the respiratory tract (Clark, 2009). Extrapulmonary infections due to *Nocardia* can occur up to 50% of immunocompromised patients with pulmonary nocardiosis (Clark, 2009). More than 80 taxonomically distinct species of genus *Nocardia* have been described; 33 are known to be pathogenic to humans or animals (Saubolle and Sussland, 2003). *Nocardia beijingensis* was first isolated from

soil in China in 2001 (Wang *et al*, 2001). Human cases due to this species have been reported from Thailand and Japan where it presented with pulmonary and systemic manifestations (Kageyama *et al*, 2004).

Phaeohyphomycosis is an infection caused by dematiaceous molds and rarely causes infection in renal transplant recipient (Schieffelin *et al*, 2014). The most common clinical manifestation of phaeohyphomycosis is skin and soft tissue infection (Husain *et al*, 2003). Due to limited data regarding antifungal susceptibilities this pathogen is usually treated with surgical debridement along with combination antifungal therapy (Clancy *et al*, 2000; Schieffelin *et al*, 2014). We report here the first case of psoas abscess caused by *N. beijingsensis* in a renal transplant recipient and subcutaneous phaeohyphomycosis caused by *Phaeoacremonium parasiticum* mimicking pyogenic cellulitis of the right leg of the same patient during the same hospitalization.

### CASE REPORT

A 58 year-old man with adult polycystic kidney disease and renal failure received a cadaveric renal transplant in February 2002. He was placed on cyclosporine and prednisolone. The transplanted organ initially functioned well. His renal function began to decline 10 years after transplant and a renal biopsy showed antibody-mediated rejection. He received intravenous immunoglobulin and his immunosuppressive drugs were changed to mycophenolate mofetil, tacrolimus and prednisolone. In October 2013, he developed cytomegalovirus (CMV) colitis which was successfully treated with a course of ganciclovir.

Two months prior to admission (December, 2013), the patient complained

of fever, fatigue, decrease appetite and 7 kilograms weight loss. He was admitted to the hospital complaining of left lower abdominal (transplanted kidney area), left groin pain and limited movement of his left hip for 1 week.

On physical examination, he appeared ill looking and his temperature was 39°C but his other vital signs were normal. There were crackles in both his lung fields. Abdominal examination revealed left lower quadrant tenderness. There was an ascites detected. His left hip was held in a flexed position and he was unable to fully extend it. He had a positive psoas sign on the left.

Laboratory evaluation showed white blood cell (WBC) count of 14,880 cells/mm<sup>3</sup> with 94% neutrophils, a blood urea nitrogen of 64 mg/dl, a serum creatinine of 3.29 mg/dl, a sodium (Na) level of 130 mEq/l, a potassium (K) level of 3.8 mEq/l, a chloride (Cl) level of 91 mEq/l, and a bicarbonate (HCO<sub>3</sub>) level of 25 mEq/l. His liver function tests were normal. A chest radiograph showed bilateral nodular opacities (Fig 1A) and a computed tomography (CT) of the chest and abdomen revealed areas of multifocal small centrilobular nodules scattered in both lower lobes of the lungs (Fig 1B) and a large heterogeneous enhancing hyperdense lesion, approximately 5 X 5 cm in diameter and more than 8 cm long, originating from the lower pole of transplanted kidney extending into the left iliopsoas muscle (Fig 1C). Percutaneous drainage (PCD) of the psoas abscess was conducted under ultrasound guidance and revealed 100 ml of frank pus. A Gram-stain smear of the pus showed numerous filamentous, branching, gram-positive rods. A modified acid-fast stain was positive for filamentous, branching bacteria (Fig 1 D and 1E). Two days later, the pus culture grew an organ-

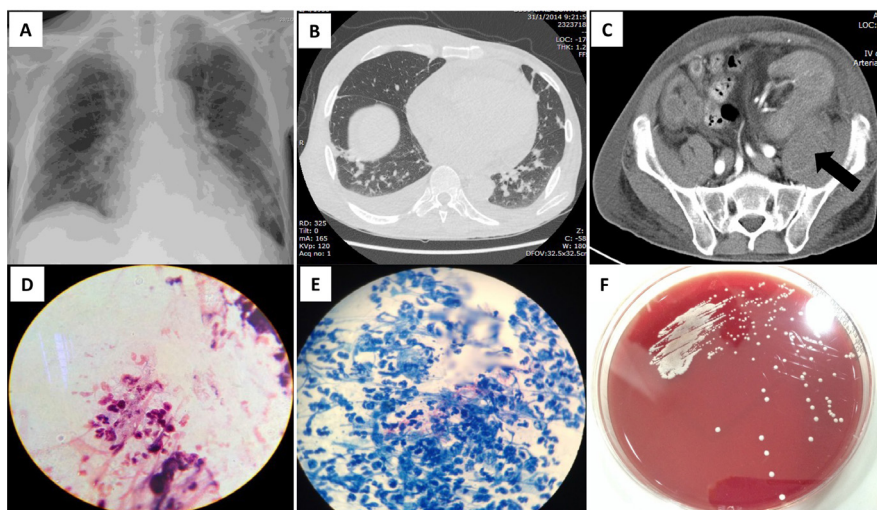


Fig 1–(A) Chest radiograph showed bilateral nodular opacities; (B) a CT of the chest showing multifocal small centrilobular nodules in both lower lobes; (C) a CT of the abdomen revealing a large heterogeneous enhancing hyperdense lesion, approximately 5 X 5 cm in diameter and more than 8 cm long, originated from the lower pole of transplanted kidney extending into the left iliopsoas muscle (arrow); (D) A Gram stain of the abscess pus showing numerous filamentous, branching, gram-positive rods; (E) a modified acid-fast stain of the abscess pus showing filamentous branching bacteria; (F) colony morphology of the *Nocardia* isolated from this patient.

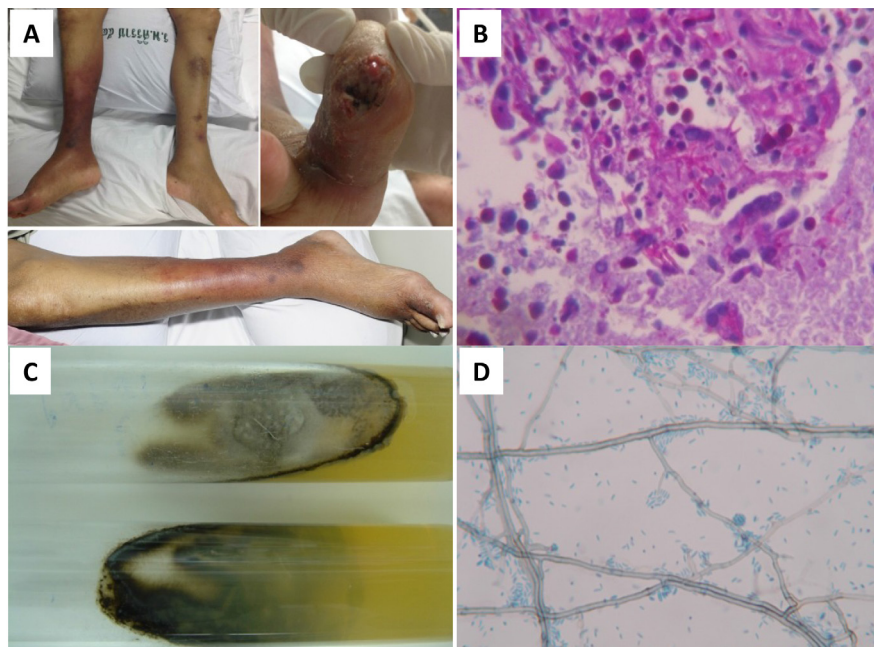


Fig 2–(A) Skin lesions on the right leg of the patient; (B) Periodic acid-Schiff stain of the skin biopsy specimen showing dark-walled toruloid hyphae; (C) a fungal culture from the biopsied skin grew a dematiaceous mold; (D) microscopic examination of the mycelium showing dark-walled septate hyphae and cylindrical conidiophores tapering toward the tips.

ism with small chalky colonies (Fig 1F). The bacterium was finally identified as *N. beijingensis* using 16S rRNA gene sequence analysis. Antimicrobial susceptibility testing showed the organism was susceptible to trimethoprim/sulfamethoxazole (TMP/SMX), amikacin, imipenem, linezolid and tobramycin, but resistant to amoxicillin-clavulanate, ceftriaxone and moxifloxacin. Bronchoscopy was not performed. The patient received treatment with high dose intravenous TMP/SMX for 6 weeks, and during the first 2 weeks it was combined with imipenem. After that the patient was changed to oral TMP/SMX. His immunosuppressive agents were tapered down. His fever subsided completely by 7 days of treatment and the drain was removed. After 8-weeks treatment abdominal ultrasonography showed no residual abscess and his chest radiograph was normal.

By ten weeks of treatment, he developed an erythematous plaque with multiple subcutaneous nodules on his right leg, mimicking bacterial cellulitis, with abscess formation of the right big toe (Fig 2A). This was initially treated as bacterial cellulitis with intravenous meropenem and fosfomycin for 2 weeks without improvement. A tissue biopsy was performed of the right big toe lesion which revealed dark-walled septate toruloid hyphae on a periodic acid-Schiff (PAS) stain (Fig 2B). A culture of the biopsied skin revealed slow growing mold colonies which were initially whitish-grey in color and became olivaceous-grey with age (Fig 2C). Micromorphology showed moderately thin dark-walled toruloid septate hyphae with cylindrical conidiophores tapering towards the tips (Fig 2D). The small funnel-shaped collarettes usually found on the tip of the organism, which is characteristic of the genus *Phaeoacremonium* were not clearly seen. Therefore, an ITS1 sequence of the

fungus was performed and the organism was finally identified as *P. parasiticum*. The patient was treated with surgical drainage and a 4-week course of intravenous liposomal amphotericin B (5 mg/kg/day). His skin lesions improved markedly and his treatment was changed to oral itraconazole in combination with terbinafine for 5 months.

## DISCUSSION

The prevalence of nocardial infections in solid organ transplant recipients varies from 0.7% to 3.5% (Clark, 2009); the majority of patients have pneumonia with or without systemic involvement. Infection caused by *Nocardia* rarely presents as an isolated psoas muscle abscess; only one case has been reported in the literature (Shohaib, 1994). Our patient had a *N. beijingensis* psoas abscess and abnormal lung lesions which resolved with treatment. Although we did not obtain a respiratory specimen for microbiological examination, we believe the pulmonary infection was most likely due to *Nocardia*.

The first 6 months period post-transplantation is the period with the greatest risk for *Nocardia* infection (Yu *et al*, 2011). The time to develop *Nocardia* infection after transplantation varies from 26 days to 22 years with a mean interval of 34.41 months (Yu *et al*, 2011). Patients with previous graft rejection may develop *Nocardia* infection much earlier, with a mean interval of 15.77 months (Yu *et al*, 2011). Our patient developed *Nocardia* infection approximately 15 months after receiving treatment for organ rejection.

The first case of human infection caused by *N. beijingensis* was reported in 2004 (Kageyama *et al*, 2004). Since then, several reports of *N. beijingensis* infection have been published and the



majority of cases have been pulmonary nocardiosis and primary subcutaneous abscesses (Martinaud *et al*, 2011; Ogawa *et al*, 2011; Derancourt *et al*, 2012; Ohmori *et al*, 2012). This is the first reported case of psoas abscess caused by *N. beijingensis* successfully treated with a combination antimicrobial agents and drainage. Previous data revealed *N. beijingensis* is susceptible to TMP/SMX, amikacin, tobramycin, and imipenem but may resistant or susceptible to ceftriaxone, minocycline and moxifloxacin (Kageyama *et al*, 2004; Martinaud *et al*, 2011; Ogawa *et al*, 2011; Ohmori *et al*, 2012). This antimicrobial susceptibility pattern is similar to that of our isolate.

Subcutaneous phaeohyphomycosis in organ transplant recipient usually occurs late (more than 2 years post-transplantation) (Singh *et al*, 1997). Lesions were typically painless, and the infection has an indolent course, smoldered for weeks to months, and most commonly found at the lower extremities (Marques *et al*, 2006). Skin lesions due to dematiaceous fungi can present as papules, plaques, pustules, nodules, non-healing ulcers, or erythematous lesions on the extremities that mimic bacterial cellulitis (Singh *et al*, 1997). Many patients, similar to ours present with subcutaneous phaeohyphomycosis and are initially treated as bacterial cellulitis (Singh *et al*, 1997). There were 11 cases of *P. parasiticum* infection reported in one case series (Baddley *et al*, 2006), 4 of these 11 cases presented as skin and soft tissue infections in renal recipients. The spectrum of clinical manifestations of *P. parasiticum* infection range from subcutaneous infection to fungemia (Heath *et al*, 1997; Baddley *et al*, 2006). Surgical debridement and use of antifungal agents, such as amphotericin B, extended-spectrum triazoles, terbinafine

and 5FC are associated with relatively good outcomes (Baddley *et al*, 2006). In our patient, a favorable outcome was achieved following extensive incision and drainage of skin abscesses and combination antifungal therapy.

In conclusion, we reported a rare case of a psoas muscle abscess due to *N. beijingensis* and subcutaneous phaeohyphomycosis due to *P. parasiticum* in a renal transplant recipient. Identification of the *Nocardia* species and antibiotic susceptibility testing are important to guide treatment to achieve a favorable outcome. Skin and soft tissue lesions in a transplant recipient can be caused by a dematiaceous fungus that may mimic bacterial cellulitis. Therefore, skin biopsy for histopathology and culture is highly recommended in similar cases.

#### ACKNOWLEDGEMENTS

The authors would like to thank the infectious disease clinical fellows and residents for providing the clinical information and patient care. Methee Chaya-kulkeeree, Piriyaorn Chongtrakool and Popchai Ngamskulrungraj are supported by a "Chalermphrakiat" Grant, Faculty of Medicine Siriraj Hospital, Mahidol University. The authors declare no conflicts of interest.

#### REFERENCES

- Baddley JW, Mostert L, Summerbell RC, Moser SA. *Phaeoacremonium parasiticum* infections confirmed by beta-tubulin sequence analysis of case isolates. *J Clin Microbiol* 2006; 44: 2207-11.
- Clancy CJ, Wingard JR, Nguyen MH. Subcutaneous phaeohyphomycosis in transplant recipients: review of the literature and demonstration of in vitro synergy between antifungal agents. *Med Mycol* 2000; 38: 169-75.

- Clark NM. Nocardia in solid organ transplant recipients. *Am J Transplant* 2009; 9: S70-7.
- Derancourt C, Theodose R, Deschamps L, et al. Primary cutaneous nocardiosis caused by *Nocardia beijingensis*. *Br J Dermatol* 2012; 167: 216-8.
- Heath CH, Lendrum JL, Wetherall BL, Wes-selingh SL, Gordon DL. *Phaeoacremonium parasiticum* infective endocarditis following liver transplantation. *Clin Infect Dis* 1997; 25: 1251-2.
- Husain S, Alexander BD, Munoz P, et al. Opportunistic mycelial fungal infections in organ transplant recipients: emerging importance of non-aspergillus mycelial fungi. *Clin Infect Dis* 2003; 37: 221-9.
- Kageyama A, Poonwan N, Yazawa K, Mikami Y, Nishimura K. *Nocardia beijingensis*, is a pathogenic bacterium to human: the first infectious cases in Thailand and Japan. *Mycopathologia* 2004; 157: 155-61.
- Lebeaux D, Morelon E, Suarez F, et al. Nocardiosis in transplant recipients. *Eur J Clin Microbiol Infect Dis* 2014; 33: 689-702.
- Marques SA, Camargo RMP, Summerbell RC, et al. Subcutaneous phaeohyphomycosis caused by *Phaeoacremonium parasiticum* in a renal transplant patient. *Med Mycol* 2006; 44: 671-6.
- Martinaud C, Verdonk C, Bousquet A, et al. Isolation of *Nocardia beijingensis* from a pulmonary abscess reveals human immunodeficiency virus infection. *J Clin Microbiol* 2011; 49: 2748-50.
- Ogawa T, Kasahara K, Yonekawa S, et al. *Nocardia beijingensis* pulmonary infection successfully treated with intravenous beta-lactam antibiotics and oral minocycline. *J Infect Chemother* 2011; 17: 706-9.
- Ohmori S, Kobayashi M, Yaguchi T, Nakamura M. Primary cutaneous nocardiosis caused by *Nocardia beijingensis* in an immunocompromised patient with chemotherapy for advanced prostate cancer. *J Dermatol* 2012; 39: 740-1.
- Saubolle MA, Sussland D. Nocardiosis: review of clinical and laboratory experience. *J Clin Microbiol* 2003; 41: 4497-501.
- Schieffelin JS, Garcia-Diaz JB, Loss GE, et al. Phaeohyphomycosis fungal infections in solid organ transplant recipients: clinical presentation, pathology, and treatment. *Transpl Infect Dis* 2014; 16: 270-8.
- Shohaib S. Nocardial psoas and perinephric abscess in a renal transplant treated by surgery and antibiotics. *Nephrol Dial Transplant* 1994; 9: 1209-10.
- Singh N, Chang FY, Gayowski T, Marino IR. Infections due to dematiaceous fungi in organ transplant recipients: case report and review. *Clin infect Dis* 1997; 24: 369-74.
- Wang L, Zhang Y, Lu Z, et al. *Nocardia beijingensis* sp. nov., a novel isolate from soil. *Int J System Evol Microbiol* 2001; 51(Pt 5): 1783-8.
- Yu X, Han F, Wu J, et al. Nocardia infection in kidney transplant recipients: case report and analysis of 66 published cases. *Transpl Infect Dis* 2011; 13: 385-91.