

CASE SERIES

CATHETER-RELATED BLOODSTREAM INFECTIONS CAUSED BY *TRICHOSPORON* SPECIES

Ratima Issarachaikul¹, Orapin Lertwannawit¹, Pitaks Detporntewan¹,
Noppacharn Uaprasert², Rongpong Plongla¹, Shanop Shuangshoti³,
Ariya Chindamporn⁴ and Chusana Suankratay¹

¹Division of Infectious Diseases, Department of Medicine, ²Division of Hematology, Department of Medicine, ³Department of Pathology, ⁴Department of Microbiology, Faculty of Medicine, Chulalongkorn University, Bangkok, Thailand

Abstract. Trichosporonosis is an emerging invasive opportunistic fungal infection in immunocompromised patients. We report 5 catheter related blood stream infections caused by *Trichosporon* species over a five-year period at King Chulalongkorn Memorial Hospital, Bangkok, Thailand. All the patients were immunocompromised, had received broad-spectrum antibiotics and had a central venous catheter or arterial line inserted for a mean duration of 16.2 days (range 10-30 days). Four patients developed disseminated infection and only 2 survived, giving a mortality rate of 60%. Because of the prevalence of *Trichosporon* catheter related blood stream infections at our institute, health care providers should have a high index of suspicion for *Trichosporon* species infections in patients with risk factors and prolonged presence of a central venous catheter.

Keywords: *Trichosporon*, trichosporonosis, catheter-related bloodstream infection, invasive fungal infection, yeast

INTRODUCTION

Trichosporon species, yeast-like fungi, are a known cause of white piedra, superficial skin infections, and onychomycosis (Chagas-Neto *et al*, 2008). They rarely cause invasive infections. Trichosporonosis is an emerging cause of invasive fungal infection in immunocompromised individuals (Kontoyiannis *et al*, 2004; Girmenia *et al*, 2005; Ruan *et al*, 2009; Suzuki

et al, 2010; Chitasombat *et al*, 2012). Apart from host factors, previous and/or current use of broad-spectrum antibiotics and the presence of a central venous catheter (CVC) are recognized as predisposing factors for trichosporonosis (Kontoyiannis *et al*, 2004; Ruan *et al*, 2009; Caira *et al*, 2011; Colombo *et al*, 2011; Chitasombat *et al*, 2012).

CVCs and arterial (A) lines are frequently used in medical practice, especially in patients in the intensive care unit, who have received chemotherapy or organ transplantation. Both infectious and noninfectious complications associated with CVC and A-lines have been recognized as a cause of morbidity and

Correspondence: Dr Chusana Suankratay, Division of Infectious Disease, Department of Medicine, Faculty of Medicine, Chulalongkorn University, Bangkok 10330, Thailand.
Tel/Fax: 66 (0) 2256 4578
E-mail: schusana@hotmail.com

mortality in these patients (McGee and Gould, 2003). Infectious complications include exit site, tunnel, and catheter-related bloodstream infections (CRBSI) (McGee and Gould, 2003). Lorente *et al* (2005) reported the incidences of catheter-associated local infections and CRBSI as 6.05 and 2.79 per 1,000 catheter-days, respectively. *Staphylococcus* species and *Candida* species are the most common pathogens causing CRBSI due to their ability to adhere to intravascular devices and form biofilm. Despite its ability to form biofilm (Di Bonaventura *et al*, 2006), *Trichosporon* species are rarely reported as causative pathogens (Kontoyiannis *et al*, 2004; Girmenia *et al*, 2005; Ruan *et al*, 2009; Suzuki *et al*, 2010; Caira *et al*, 2011; Chitasombat *et al*, 2012). Here, we report 5 cases of CRBSI caused by *Trichosporon* species over a five-year period at King Chulalongkorn Memorial Hospital, Bangkok, Thailand.

CASE SERIES

Case 1

A 31-year-old female was hospitalized with acute psychosis for 3 days. She had a history of systemic lupus erythematosus (SLE) for 12 years with the main manifestations being a neuropsychiatric disorder, nephritis, and autoimmune hemolytic anemia. She had been taking prednisolone at 30 mg/day for 3 months. During hospitalization, she was diagnosed active SLE and myocarditis, a neuropsychiatric disorder, and nephritis. Intravenous pulse methylprednisolone and cyclophosphamide were given. She developed respiratory failure and needed prolonged intubation and mechanical ventilation.

Six weeks after admission, she developed multidrug-resistant (MDR) *Acinetobacter baumannii* pneumonia with septic

shock, and was treated with meropenem, cefoperazone/sulbactam, and ampicillin/sulbactam. Caspofungin was initiated for fungal prophylaxis due to long-term use of steroids. Her clinical condition gradually improved. Two weeks later, she developed a high-grade fever with a septic shock. Tigecycline and trimethoprim-sulfamethoxazoles were added and the CVC was removed. Twenty-seven hours after being obtained, blood culture taken from a double-lumen catheter in her right femoral vein grew *Trichosporon* sp. The species of *Trichosporon* was not identified due to the complicated testing needed. She died within 2 days before the results were reported. She had not been given antifungal treatment.

Case 2

A 37-year-old male with a history of heavy smoking presented with angina during exertion 30 minutes prior to admission, and was diagnosed with acute ST elevation myocardial infarction of the anterior wall of the heart with cardiogenic shock. A coronary angiogram was performed revealing 70% stenosis of the proximal left anterior descending coronary artery, 80%, 99%, and 100% stenosis of the proximal, middle, and distal right circumflex coronary artery, respectively. Coronary angioplasty could not be performed due to unstable hemodynamics. Conservative treatment with inotropic agents and an intra-aortic balloon pump were initiated. Four weeks after admission, the patient underwent an orthotopic heart transplantation. He received antithymocyte globulin, mycophenolate mofetil, and methylprednisolone as immunosuppressive agents. Fluconazole at a dose of 50 mg/day and trimethoprim-sulfamethoxazole 2 tablets/day were also prescribed to prevent fungal and *Pneumocystis jirovecii* infections, respectively.

Five weeks after admission, the patient developed multi-drug resistant *Acinetobacter baumannii* pneumonia, which was responsive to treatment with meropenem, ampicillin/sulbactam and colistin. Five days later, he developed a new fever and several eschars and nodules on his nose, chin, and anterior chest wall: *Trichosporon asahii* A-line-associated bloodstream infection was diagnosed. The A-line was removed, and amphotericin B was given before the fungal species was diagnosed. The sepsis could not be controlled and the patient died five days later.

Case 3

An 89-year-old female was diagnosed with acute non-ST elevation myocardial infarction with congestive heart failure. She also had a history of diabetes mellitus and hypertension. She developed severe respiratory distress and was intubated and placed on ventilatory support.

After seven weeks of hospitalization, she developed multi-drug resistant *A. baumannii* pneumonia with adult respiratory distress syndrome (ARDS), and was treated with imipenem, cefoperazone/sulbactam and colistin. Dexamethasone was given to treat ARDS. Nine days later, her condition worsened. A chest X-ray showed progressive pulmonary infiltrates. Her sputum and urine Gram stain revealed numerous neutrophils and many budding yeast cells with pseudohyphae, but without true septate hyphae. Intravenous fluconazole at 200 mg/day was added for suspected systemic *Candida* infection. Four days after incubation, *T. asahii* was isolated from a blood culture taken from a triple-lumen catheter in her right internal jugular vein. She developed refractory septic shock with multiorgan dysfunction and died 7 days after initiating fluconazole treatment and CVC removal.

Case 4

A 1-month-old male was referred for correction of congenital cyanotic heart disease, Taussig-Bing Complex. During hospitalization, a modified Blalock-Taussig and patent ductus arteriosus shunts was placed. One day post operation, the patient developed right upper lobe pneumonia with septic shock, and was treated with meropenem and vancomycin. Sputum and blood cultures grew no organisms. One week after treating with antibiotics, his clinical condition had not improved. A septic work-up was performed again. A sputum Gram stain revealed many neutrophils and budding yeast cells. Blood cultures taken from a double-lumen subclavian catheter grew yeast. Fluconazole at 3 mg/kg/day was initiated for suspected *Candida* pneumonia. The organism was finally identified as *Trichosporon* sp. The species of *Trichosporon* could not be identified due to the inability to complete the necessary testing. The newborn made a complete recovery after a 7-day course of fluconazole without CVC removal. He was discharged home after 95 days in the hospital.

Case 5

A 38-year-old male was hospitalized for the first phase of induction chemotherapy for acute lymphoid leukemia. A single-lumen catheter was inserted into his right subclavian vein on the third day of hospitalization. After completion of chemotherapy, he developed febrile neutropenia which was caused by primary *Aeromonas sobria* bacteremia and treated with meropenem. Five days after meropenem treatment, amphotericin B was added because of persistent fever and neutropenia. Four weeks after hospitalization he developed another fever spike. Physical examination revealed pure horizontal

nystagmus of both eyes and an impaired finger-to-nose test in the right side. A chest X-ray showed two faint nodules in the right middle lobe of the lung. A computed tomogram (CT) scan of the brain showed a 2-cm abscess in the cerebellar vermis (Fig 1). An abdominal ultrasonogram revealed multiple lesions, 0.5-1 cm in size, in the liver and spleen. While waiting for the results of investigations, the patient was empirically treated with meropenem, cefoperazone/sulbactam, vancomycin, and caspofungin. Budding yeast cells, pseudohyphae and true septate hyphae (Fig 2) were isolated from a single-lumen subclavian catheter. The caspofungin was changed to intravenous voriconazole to treat suspected *Trichosporon* CRBSI. The CVC was removed and a culture of the catheter grew *T. asahii*. One week after voriconazole treatment the cerebellar abscess was removed but a culture still grew *T. asahii*. The patient also developed a subcutaneous abscess in his right groin which was then aspirated and the culture of the pus grew *T. asahii*. The patient gradually improved, and was able to complete his second phase of induction chemotherapy without a relapse of the *Trichosporon* infection. He did well with oral voriconazole, and was discharged home after 98 days of hospitalization.

The 5 cases are summarized in Table 1.

DISCUSSION

Trichosporon species are naturally present in the soil, water, and other environmental substances (Chagas-Neto *et al*, 2008; Colombo *et al*, 2011). In humans, *Trichosporon* species may colonize the genital skin, urinary tract and invasive devices, probably before causing invasive trichosporonosis (Silvestre *et al*, 2010). *Trichosporon* species can be the normal flo-

ra of the respiratory and gastrointestinal tracts (Chagas-Neto *et al*, 2008; Colombo *et al*, 2011).

Currently, of the 50 identified species of genus *Trichosporon*, 16 species are of clinical importance. *T. asahii* is among the most commonly reported *Trichosporon* species causing invasive trichosporonosis worldwide (Kontoyiannis *et al*, 2004; Girmenia *et al*, 2005; Chagas-Neto *et al*, 2008; Ruan *et al*, 2009; Suzuki *et al*, 2010; Colombo *et al*, 2011; Chitasombat *et al*, 2012). *Trichosporon* species may have blastoconidia, arthroconidia, true hyphae and pseudohyphae (Larone, 1995; Colombo *et al*, 2011). *Trichosporon* colonies are at first cream colored, moist and soft and then the surface may become wrinkled and the color darkens to yellowish grey. On cornmeal-Tween 80 agar trichosporon species have true hyphae, pseudohyphae, and blastoconidia; arthroconidia are formed on older cultures (Larone, 1995). The genera *Geotrichum* and *Blastoschizomyces capitatus* can also produce arthroconidia and true hyphae (Larone, 1995; Collier *et al*, 1998) but have a negative urease test, in contrast to the positive urease test with *Trichosporon* species (Larone, 1995; Colombo *et al*, 2011).

The fungal ribosomal RNA (rRNA) gene and the spacer regions [internal transcribed spacer (ITS) and intergenic spacer (IGS)] are used for fungal identification. Mekha *et al* (2010) studied 5 genotypes of *Trichosporon* in Thailand; only 2 genotypes (1 and 3) were prevalent.

In Thailand, there are handful reports of invasive trichosporonosis. To our knowledge, there has never been a published report of invasive trichosporonosis at King Chulalongkorn Memorial Hospital. Our case series is the first published study at our institute. A previous

Table 1
A summary of the 5 patients with catheter-related bloodstream infection (CRBSI) caused by *Trichosporon* species at our institution.

No	Sex/ age (year)	Current diagnosis	Predisposing condition			LOH (day)	<i>Trichosporon</i> species	Diagnosis			Treatment		Outcome	
			Immunosuppressive condition	Immunosuppressive agent	Antibiotics used			Antifungal treatment (duration)	Type and site (DOI, days)	Disseminated to organs	Medication	Catheter removed		Surgery
1	F/31	Systemic lupus erythematosus	No	Pulse MPS, CYC, dexamethasone	CIP, IMI, MER, CFP/SUL, AMP/SUL, TIG	CAS (12 days)	61	<i>T. species</i>	DL, femoral vein (17)	Lungs	No	Yes	No	Died 2 days after diagnosis
2	M/37	Acute MI	Heart transplant	ATG, MMF, prednisolone	PIP/TAZ, MER, vancomycin, colistin, CRO, AMP/SUL, TMP/SMX	FLU (13 days)	47	<i>T. asdiii</i>	A line, radial artery (11)	Pericardium, AMB lungs, skin	Yes	Yes	No	Died after 5 days of AMB treatment
3	F/89	Acute MI	Diabetes mellitus	Dexamethasone	AMP/SUL, MER, No colistin, CFP/SUL, IMI	No	61	<i>T. asdiii</i>	TL, internal jugular vein (13)	Lungs, kidneys	FLU	Yes	No	Died after 2 days of FLU treatment
4	M/1 month	Congenital heart disease	Neonate	No	CAZ, CLX, MER, vancomycin	No	12	<i>T. species</i>	DL, subclavian vein (10)	No	FLU	No	No	Survived with 7 days of FLU treatment
5	M/38	ALL	ALL	VIN, DOX, LAS, prednisolone	CAZ, MER	AMB (14 days)	28	<i>T. asdiii</i>	SL, subclavian vein (30)	Brain, lungs, liver, spleen, skin	VOR	Yes	Yes (cerebellar abscess)	Survived with >60 days of VOR treatment

F, female; M, male; MI, myocardial infarction; ALL, acute lymphoid leukemia; LOH, length of hospitalization; DOI, duration of insertion before CRBSI development; SL, single-lumen catheter; DL, double-lumen catheter; TL, triple-lumen catheter; MPS, methyl prednisolone; CYC, cyclophosphamide; ATG, anti-thymocyte globulin; MMF, mycophenolate mofetil; VIN, vincristine; DOX, doxorubicin; LAS, L-asparaginase; CIP, ciprofloxacin; CRO, ceftriaxone; CAZ, ceftazidime; CLX, cloxacillin, PIP/TAZ, piperacillin/tazobactam; MER, meropenem, IMI, imipenem, CFP/SUL, cefoperazone/sulbactam; AMP/SUL, ampicillin/sulbactam; TIG, tigecycline; TMP/SMX, trimethoprim/sulfamethoxazole; FLU, fluconazole; VOR, voriconazole; AMB, amphotericin B; CAS, caspofungin.

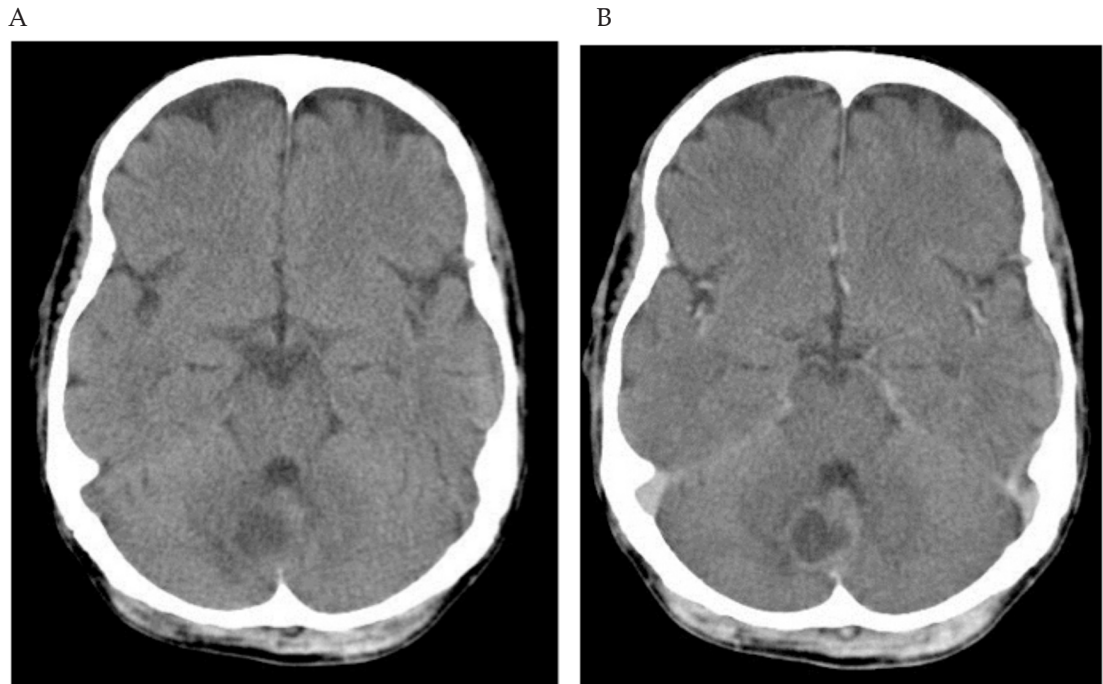


Fig 1—Cranial computed tomogram showing a 2-cm abscess in the cerebellar vermis. A. Precontrast film; B. Postcontrast film.

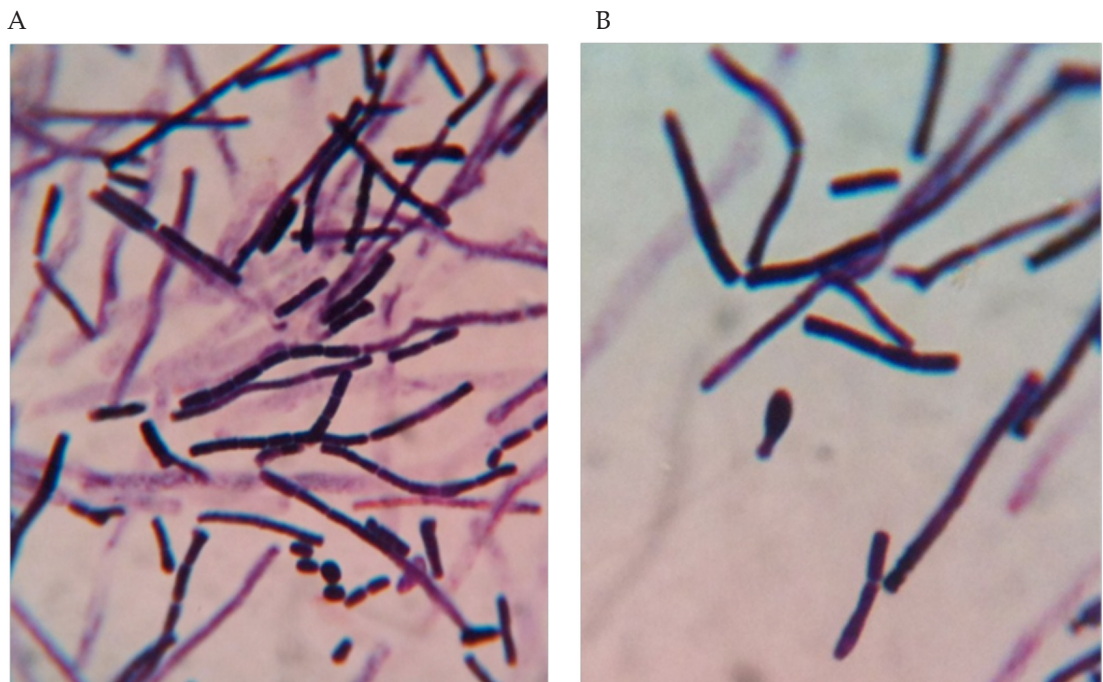


Fig 2—Gram stain of a blood culture specimen showing the morphological characteristics of *Trichosporon asahii*, including blastoconidia, arthroconidia, true hyphae, and pseudohyphae.

study at our institute found filamentous mold and *Candida* were the only causative fungi in patients with febrile neutropenia (Roongpoovapatr and Suankratay, 2010). Since then, most patients with a hematologic malignancy, such as acute leukemia who have a stem cell transplant have a CVC placed. The variety of causative agents of febrile neutropenia, especially pathogens associated with biofilm within CVC has increased. *Trichosporon* is one of those pathogens. A study of fungemia in non-HIV-infected patients at Khon Kaen Hospital, northeastern Thailand, during 1998-2003 found *Trichosporon* infection accounted for 6.1% of cases (Anunnatsiri *et al*, 2009). Another study carried out at the Mycology Laboratory of the Thai National Institute of Health during 2003-2007 found the most frequently isolated yeast was *Candida* species, followed with *Cryptococcus neoformans*. *Trichosporon* species were isolated in 2-7% (Mekha *et al*, 2010).

In our case series, *Trichosporon* sp was the cause of CRBSI. Our findings are similar to other reports (Girmenia *et al*, 2005; Ruan *et al*, 2009). All the patients in our series were immunocompromised, either from preexisting diseases or immunosuppressive agents, had received several courses of broad-spectrum antibiotics and had a CVC or A line placed for a mean duration of 16.2 days (range: 10-30 days). A breakthrough *Trichosporon* infection was observed in a patient receiving antifungal treatment (amphotericin B, fluconazole, and caspofungin) in 3 of our patients. This is similar to a report by Chitasombat *et al* (2012), but only 20% of patients in their study had disseminated trichosporonosis. In our case series, 2 patients survived, giving a mortality rate of 60%. One survivor was a neonate with CRBSI without evidence of dissemination to other organs. Surprisingly, he survived with only fluco-

nazole treatment without removal of the double-lumen catheter. This patient may have only been colonized with *Trichosporon* in the lumen of the CVC, similar to 3 surviving cases with *Trichosporon* colonization of the CVC reported by Salazar *et al* (2002). The other patient who survived in our series had acute leukemia and *T. asahii* CRBSI with dissemination to the brain, liver, and spleen. The patient was treated with both medical (voriconazole) and surgical (cerebellar abscess) methods in addition to removing the CVC.

Voriconazole is probably the most effective antifungal agent against *Trichosporon* species. In an *in vitro* study from China all the clinical isolates of *T. asahii* were susceptible to voriconazole (Collier *et al*, 1998). In Thailand, Mekha *et al* (2010) studied the minimum inhibitory concentrations (MICs) of 6 antifungal agents against *T. asahii* from clinical isolates. The isolates had decreased susceptibility to amphotericin B, 5-flucytosine, miconazole, fluconazole, and itraconazole, but voriconazole had a mean MIC of 0.09 µg/ml. Other studies describe successful treatment of a patient with acute leukemia and *T. asahii* fungemia using voriconazole (Asada *et al*, 2006; Xia *et al*, 2012). Pfaller *et al* (2009) found 4% of *Trichosporon* species were resistant to voriconazole in a study from Asia-Pacific countries. In 1994, prior to the wide availability of voriconazole, trichosporonosis in mice could be successfully treated with amphotericin B and fluconazole (Anaissie *et al*, 1994). Hosokawa *et al* (2012) reported successful treatment of *Trichosporon* fungemia with amphotericin B and voriconazole in a stem cell transplant recipient. However, to our knowledge, no randomized controlled studies regarding the first-line treatment for trichosporonosis have been reported.

In addition to appropriate antifungal

treatment, adequate surgical drainage is needed in patients with larger abscesses. The adult patient who survived in our series was treated surgically for his cerebellar and subcutaneous abscesses. Another study reported successful treatment of a *Trichosporon* brain abscess with surgical drainage and antifungals (Basiri *et al*, 2012).

According to the Infectious Diseases Society of America (IDSA) guidelines, a CVC should be removed in all patients with a CRBSI caused by *Candida* species (Mermel *et al*, 2009), even though a recent randomized controlled study showed early CVC removal in *Candida* CRBSI was not associated with any clinical benefit (Nuccir *et al*, 2010). Despite randomized controlled study evidence, CVC should be removed from all patients with *Trichosporon* CRBSI (Raad *et al*, 2004; Nucci *et al*, 2005).

Since there has been an increasing use of CVC and A-lines at our institute, it is likely there will be an increasing occurrence of both infectious and noninfectious complications associated with those intravascular devices. Strategies needed to prevent these complications are recommended by the Healthcare Infection Control Practices Advisory Committee (HICPAC) and need to be implemented by our institute (O'Grady *et al*, 2011).

In conclusion, trichosporonosis is an emerging invasive opportunistic fungal infection in immunocompromised patients. Because of the increasing prevalence of *Trichosporon* CRBSI at our institute, a high index of suspicion of this infection should be made in all patients with predisposing factors and prolonged CVC use.

REFERENCES

- Anaissie EJ, Hachem R, Karyotakis NC, *et al*. Comparative efficacies of amphotericin B, triazoles, and combination of both as experimental therapy for murine trichosporonosis. *Antimicrob Agents Chemother* 1994; 38: 2541-4.
- Anunnatsiri S, Chetchotisakd P, Mootsikapun P. Fungemia in non-HIV-infected patients: a five-year review. *Int J Infect Dis* 2009; 13: 90-6.
- Asada N, Uryu H, Koseki M, Takeuchi M, Komatsu M, Matsue K. Successful treatment of breakthrough *Trichosporon asahii* fungemia with voriconazole in a patient with acute myeloid leukemia. *Clin Infect Dis* 2006; 43: e39-41.
- Basiri K, Meidani M, Rezaie F, Soheilmader S, Fatehi F. A rare case of Trichosporon brain abscess, successfully treated with surgical excision and antifungal agents. *Neurol Neurochir Pol* 2012; 46: 92-5.
- Caira M, Trecarichi EM, Tumbarello M, Leone G, Pagano L. Uncommon yeast infections in hematological patients: from diagnosis to treatment. *Expert Rev Anti Infect Ther* 2011; 9: 1067-75.
- Chagas-Neto TC, Chaves GM, Colombo AL. Update on the genus *Trichosporon*. *Mycopathologia* 2008; 166: 121-32.
- Chitasombat MN, Kofteridis DP, Jiang Y, Tarrand J, Lewis RE, Kontoyiannis DP. Rare opportunistic (non-*Candida*, non-*Cryptococcus*) yeast bloodstream infections in patients with cancer. *J Infect* 2012; 64: 68-75.
- Collier L, Balows A, Sussman M. Topley & Wilson's microbiology and microbial infections 9th ed. New York: Arnold, 1998.
- Colombo AL, Padovan AC, Chaves GM. Current knowledge of *Trichosporon* spp. and trichosporonosis. *Clin Microbiol Rev* 2011; 24: 682-700.
- Di Bonaventura G, Pompilio A, Picciani C, Iezzi M, D'Antonio D, Piccolomini R. Biofilm formation by the emerging fungal pathogen *Trichosporon asahii*: development, architecture, and antifungal resistance. *Antimicrob Agents Chemother* 2006; 50: 3269-76.
- Girmenia C, Pagano L, Martino B, *et al*. Invasive infections caused by *Trichosporon* species

- and *Geotrichum capitatum* in patients with hematological malignancies: a retrospective multicenter study from Italy and review of the literature. *J Clin Microbiol* 2005; 43: 1818-28.
- Hosokawa K, Yamazaki H, Mochizuki K, *et al.* Successful treatment of Trichosporon fungemia in a patient with refractory acute myeloid leukemia using voriconazole combined with liposomal amphotericin B. *Transpl Infect Dis* 2012; 14: 184-7.
- Kontoyiannis DP, Torres HA, Chagua M, *et al.* Trichosporonosis in a tertiary care cancer center: risk factors, changing spectrum and determinants of outcome. *Scand J Infect Dis* 2004; 36: 564-9.
- Larone DH. Yeasts and yeastlike organisms. In: Larone DH, ed. Medically important fungi: a guide to identification. 3rd ed. Washington DC: ASM Press, 1995: 61-89.
- Lorente L, Henry C, Martin MM, Jimenez A, Mora ML. Central venous catheter-related infection in a prospective and observational study of 2,595 catheters. *Crit Care* 2005; 9: R631-5.
- McGee DC, Gould MK. Preventing complications of central venous catheterization. *N Engl J Med* 2003; 348: 1123-33.
- Mekha N, Sugita T, Ikeda R, *et al.* Genotyping and antifungal drug susceptibility of the pathogenic yeast *Trichosporon asahii* isolated from Thai patients. *Mycopathologia* 2010; 169: 67-70.
- Mermel LA, Allon M, Bouza E, *et al.* Clinical practice guidelines for the diagnosis and management of intravascular catheter-related infection: 2009 Update by the Infectious Diseases Society of America. *Clin Infect Dis* 2009; 49: 1-45.
- Nucci M, Anaissie E. Candidemia in patients with cancer: are persistent neutropenia and severity of illness score still relevant? *Clin Infect Dis* 2005; 40: 1063-4; author reply 4-7.
- Nucci M, Anaissie E, Betts RF, *et al.* Early removal of central venous catheter in patients with candidemia does not improve outcome: analysis of 842 patients from 2 randomized clinical trials. *Clin Infect Dis* 2010; 51: 295-303.
- O'Grady NP, Alexander M, Burns LA, *et al.* Guidelines for the prevention of intravascular catheter-related infections. *Clin Infect Dis* 2011; 52: e162-93.
- Pfaller MA, Diekema DJ, Gibbs DL, *et al.* Results from the ARTEMIS DISK Global Antifungal Surveillance Study, 1997 to 2007: 10.5-year analysis of susceptibilities of noncandidal yeast species to fluconazole and voriconazole determined by CLSI standardized disk diffusion testing. *J Clin Microbiol* 2009; 47: 117-23.
- Raad I, Hanna H, Boktour M, *et al.* Management of central venous catheters in patients with cancer and candidemia. *Clin Infect Dis* 2004; 38: 1119-27.
- Roongpoovapatr P, Suankratay C. Causative pathogens of fever in neutropenic patients at King Chulalongkorn Memorial Hospital. *J Med Assoc Thai* 2010; 93: 776-83.
- Ruan SY, Chien JY, Hsueh PR. Invasive trichosporonosis caused by *Trichosporon asahii* and other unusual *Trichosporon* species at a medical center in Taiwan. *Clin Infect Dis* 2009; 49: e11-7.
- Salazar GE, Campbell JR. Trichosporonosis, an unusual fungal infection in neonates. *Pediatr Infect Dis J* 2002; 21: 161-5.
- Silvestre AMJ, Miranda MAR, Camargo ZP. *Trichosporon* species isolated from the perigenital region, urine and catheters of a Brazilian population. *Brazilian J Microbiol* 2010; 41: 628-34.
- Suzuki K, Nakase K, Kyo T, Kohara T, *et al.* Fatal Trichosporon fungemia in patients with hematologic malignancies. *Eur J Haematol* 2010; 84: 441-7.
- Xia Z, Yang R, Wang W, Cong L. Genotyping and antifungal drug susceptibility of *Trichosporon asahii* isolated from Chinese patients. *Mycopathologia* 2012; 173: 127-33.