

CASE REPORT

MEASLES-MUMPS-RUBELLA VACCINATION INDUCED THROMBOCYTOPENIA: A CASE REPORT AND REVIEW OF THE LITERATURE

Somchai Owatanapanich¹, Nasamon Wanlapakorn², Ratsamee Tangsiri¹
and Yong Poovorawan²

¹Department of Pediatrics, King Narai Hospital, Lop Buri; ²Center of Excellence in Clinical Virology, Faculty of Medicine, Chulalongkorn University, Bangkok, Thailand

Abstract. Immune thrombocytopenia (ITP) is a disease with autoimmune destruction of platelets. ITP among children has been associated with viral infections and some vaccinations. We report a case of ITP after measles-mumps-rubella (MMR) vaccination in a 10-month-old male infant who presented with purpura and acute gastrointestinal bleeding. This case was successfully treated with corticosteroids and intravenous immunoglobulin. ITP is a rare complication of the MMR vaccine that physicians should be aware of.

Keywords: measles-mumps-rubella, immunity, thrombocytopenia

INTRODUCTION

The definition of immune thrombocytopenia (ITP) according to the International Working Group is a platelet count $<100 \times 10^9/l$ with an unexplained cause (Journeycake, 2012). The annual incidence rate for ITP varies by country from 1.1 to 5.3 per 100,000 children (Terrell *et al*, 2010). The peak age-stratified prevalence of pediatric ITP is 2-5 years (Yong *et al*, 2010). Possible etiologies of secondary ITP include chronic infection (caused by *Helicobacter pylori*, human immunodeficiency virus and hepatitis C virus), acute infec-

tion (with Epstein-Barr virus, influenza virus and Varicella zoster virus), autoimmune disorders (such as systemic lupus erythematosus, antiphospholipid syndrome and rheumatoid arthritis), certain medications, and vaccinations (Johnsen, 2012). The majority of ITP cases associated with vaccinations are attributable to the measles-mumps-rubella (MMR) vaccine, the varicella vaccine, hepatitis A vaccine, and the tetanus-diphtheria-acellular pertussis (Tdap) vaccine (O'Leary *et al*, 2012). France *et al* (2008) identified 595 children aged <18 years with ITP and found a strong correlation between MMR vaccination and the risk for developing ITP in children aged 12-23 months. The absolute risk for developing ITP after the MMR vaccine varies by country, but is estimated to be between 0.087 and 4 (median 2.6) per 100,000 doses (Mantadakis *et al*, 2010).

Correspondence: Yong Poovorawan, Center of Excellence in Clinical Virology, Department of Pediatrics, Faculty of Medicine, Chulalongkorn University, Bangkok 10330, Thailand.
Tel: +66 (0) 2256 4909; Fax: +66 (0) 2256 4929
E-mail: Yong.P@chula.ac.th

The risk of severe ITP resulting from vaccination is low. No cases of ITP associated with MMR vaccine have yet been reported for Thailand. We report here the case of a 10-month old infant who developed thrombocytopenia with bleeding after receiving the MMR vaccine. The case was successfully managed with a therapeutic platelet transfusion, corticosteroids and intravenous immunoglobulin.

CASE REPORT

A well-nourished 10-month old Thai boy living in Lop Buri Province presented with pallor, dry lips, petechiae, and purpura extensively distributed over his body and oral mucosa. He had reportedly passed dark-colored stools for 3 days. The patient had received an MMR vaccine at King Narai Hospital 8 days prior to admission. He was afebrile with a heart rate of 120 beats/min and a blood pressure of 100/60 mmHg. Cardiovascular, respiratory and neurological examinations were unremarkable. Lymph nodes, liver and spleen were not palpable. A complete blood count revealed a hemoglobin level of 10.2 g/dl, a hematocrit of 30.3%, a white cell count of $6.64 \times 10^9/l$ (31% neutrophils, 65% lymphocytes, 3% atypical lymphocytes, 1% monocytes, and no blast cells) and a platelet count of $8.5 \times 10^9/l$. A peripheral blood smear showed normochromic normocytic red cells, some polychromasia, no schistocytes, a normal white blood cells with predominant lymphocytes, and markedly decreased platelets. A coagulogram revealed a normal prothrombin time and a normal activated partial thromboplastin time. Renal and liver function tests were normal. Viral serologies (dengue NS-1 antigen, IgM, IgG, and anti-HIV) were all negative. No other cause of throm-

bocytopenia was detected. Therefore, the recent MMR vaccine was suspected as the cause of his thrombocytopenia. Because the patient had gastrointestinal bleeding from severe thrombocytopenia, intravenous immunoglobulin (IVIG) (1 g/kg/day) was administered daily for 2 days and intravenous dexamethasone at 6 mg/day was also given. On the second day of hospitalization, the patient's hematocrit decreased to 24.9%, and the platelet count decreased to $8.0 \times 10^9/l$. He was transfused with 100 ml leukocyte-poor packed red blood cells and 1 unit of platelet concentrate. The following day, his platelet count had increased to $51.7 \times 10^9/l$ and his hematocrit was stable. Three days after IVIG administration, the patient was no longer pale, and the petechiae and purpura had disappeared. He finally began passing yellow-colored stools which had previously been dark. His platelet count then increased to $100.9 \times 10^9/l$. The corticosteroid was discontinued on the fourth day of hospitalization. He was discharged home after a 5 day hospital stay with a platelet count of $165.8 \times 10^9/l$. He appeared healthy and had a normal platelet count at the follow-up visit (Fig 1).

DISCUSSION

This patient presented with an acute episode of gastrointestinal bleeding and severe thrombocytopenia eight days after MMR vaccination. After exclusion of other possible causes of thrombocytopenia, the diagnosis of MMR vaccine associated ITP was made. ITP is rarely caused by MMR and it is the only vaccine with a proven association with ITP (Cecinati *et al*, 2013). The pathogenesis is hypothesized to be the result of molecular mimicry and/or immune provocation by specific antigen exposure that activates

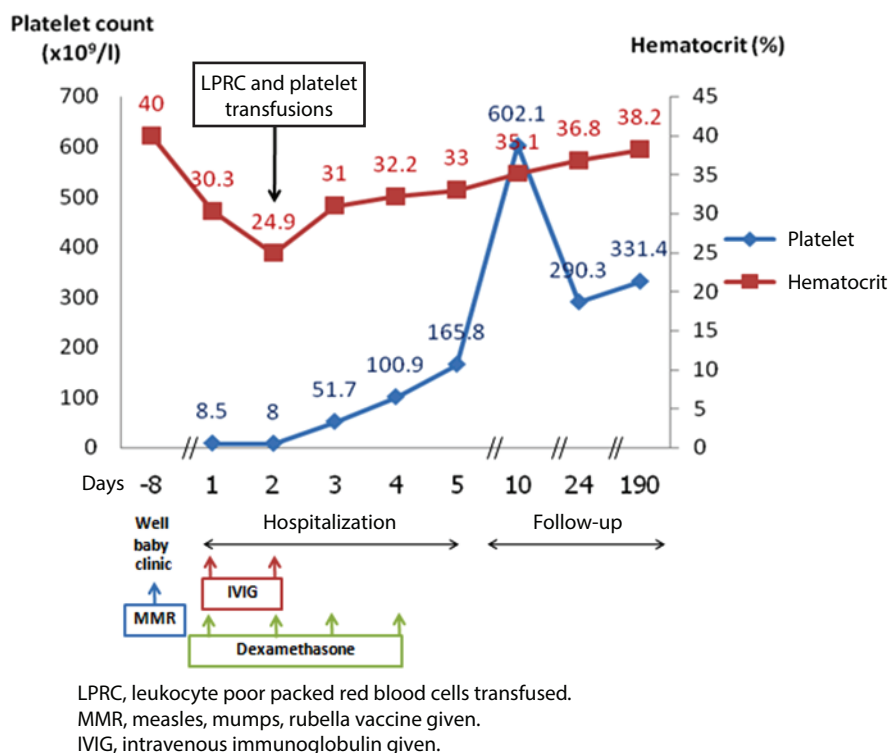


Fig 1—Serial hematocrit and platelet counts in patient with MMR vaccine associated ITP.

the immune response to platelets in susceptible individuals (Johnsen, 2012). A systematic review of the literature found 12 studies from 10 countries showing the incidence of ITP after MMR vaccination ranges from 0.087 to 4 cases per 100,000 vaccine doses (Mantadakis *et al*, 2010). This variation may be due to different surveillance methods rather than a difference in the incidence, since the incidence was higher in countries with active surveillance systems compared to those with passive surveillance systems. MMR vaccine-related ITP usually occurs within 6 weeks of vaccination (Cecinati *et al*, 2013). In most cases, clinical symptoms are mild and may include bruising and petechiae, which resolve spontaneously within a few days to a few weeks (Cecinati *et al*, 2013). One study found that of all children diagnosed with acute ITP

after MMR immunization, 93% of cases resolved within 6 months (Mantadakis *et al*, 2010). The development of chronic ITP after MMR vaccination and severe bleeding episodes in MMR-induced ITP are also rare (Kuhne *et al*, 2003). The case described here had severe thrombocytopenia with active gastrointestinal bleeding, which was treated with transfusion of packed red blood cells and platelets to prevent further complications.

The current guidelines of the Working Party of the British Committee for Standards in Haematology Task Force for initial management of children with acute ITP state that intervention is reserved for children with hemorrhage and a platelet count $<20 \times 10^9/l$ or for those with a life-threatening bleeding irrespective of the platelet count (Blanchette and Bolton-Maggs, 2008). The traditional regimen is

oral prednisolone at a dose of 2 mg/kg/day for 3-4 weeks. However, higher doses of steroids have been used and may result in a faster increase in platelet counts. Intravenous immunoglobulin, which blocks Fc-receptors on the macrophages of the reticuloendothelial system, is also the first line treatment for ITP in an emergency setting and proves effective when used at a high dose of 1-2 g/kg (Labarque and Van Geet, 2014). In this case, both intravenous immunoglobulin and high dose steroids were given to this patient due to severe bleeding and thrombocytopenia. As a result, his platelet level reached the treatment goal shortly thereafter. However, transient rebound thrombocytosis to $602 \times 10^9 /l$ was observed eight days after IVIG administration. This thrombocytosis may have been due to the decrease in destruction of the opsonized platelets via the Fc γ R system, while the number of megakaryocytes in the bone marrow is usually normal or slightly elevated in ITP patients (Cooper *et al*, 2004).

In Thailand, two doses of the measles vaccine are required because only 76% of children are protected after the first dose at 9 months of age (Techasena *et al*, 2011). Moreover, unlike many other countries, the first dose of measles vaccine in Thailand is usually given at 9 months when maternal antibodies can interfere with the vaccine efficacy in some children (Albrecht *et al*, 1977; Schlereth *et al*, 2000). Here, we report a case of MMR vaccine associated ITP presenting with life-threatening bleeding. A question arose as to whether this child should receive a second dose of MMR vaccine. According to previous studies, the risk of recurrence of ITP after repeated doses of MMR vaccine is very low. Vlachas *et al* (1996) reported a case of recurrent ITP after the third dose of MMR vaccine. A systematic

review showed among 26 children with a history of MMR vaccine induced ITP, none developed recurrence of ITP after the second dose of MMR (Mantadakis *et al*, 2010). The Immunization Monitoring Program ACTive (IMPACT) in Canada recommends measuring measles antibody titers in children with MMR vaccine related ITP before booster administration in order to decide whether a second dose is required (Sauvé and Scheifele, 2009). Since measles remains endemic in Thailand, we recommend a second dose of MMR vaccine in children with a history of MMR vaccine induced ITP due to the low risk of recurrence of ITP and the higher risk of natural measles infection; the benefits of vaccination outweigh the risk of severe thrombocytopenia associated with immunization. Nevertheless, patient education is important to raise awareness of the side effects of vaccination. Surveillance of platelet counts may be warranted in children with a history of bleeding following MMR vaccine administration.

ACKNOWLEDGEMENTS

The authors wish to thank Dr Veerasak Kronglarpcharoen and Dr Weerapat Owattanapanich for their helpful comments and Dr Sompong Vongpunsawad for reviewing the manuscript. We also thank the National Research University Project, Office of Higher Education Commission (HR1155A, WCU-001, 007-HR57), the Center of Excellence in Clinical Virology, Chulalongkorn University, the Ratchadaphiseksomphot Endowment Fund of Chulalongkorn University (RES560530093) the Outstanding Professor of the Thailand Research Fund (DPG5480002); and King Chulalongkorn Memorial Hospital Thai Red Cross Society, MK Restaurant Company Limited and The Siam Cement Pcl for supporting Prof Yong Poovorawan.

REFERENCES

- Albrecht P, Ennis FA, Saltzman EJ, Krugman S. Persistence of maternal antibody in infants beyond 12 months: mechanism of measles vaccine failure. *J Pediatr* 1977; 91: 715-8.
- Blanchette V, Bolton-Maggs P. Childhood immune thrombocytopenic purpura: diagnosis and management. *Pediatr Clin North Am* 2008; 55: 393-420, ix.
- Cecinati V, Principi N, Brescia L, Giordano P, Esposito S. Vaccine administration and the development of immune thrombocytopenic purpura in children. *Hum Vaccin Immunother* 2013; 9: 1158-62.
- Cooper N, Heddle NM, Haas M, *et al.* Intravenous (IV) anti-D and IV immunoglobulin achieve acute platelet increases by different mechanisms: modulation of cytokine and platelet responses to IV anti-D by Fcγ3a and Fcγ3b polymorphisms. *Br J Haematol* 2004; 124: 511-8.
- France EK, Glanz J, Xu S, *et al.* Risk of immune thrombocytopenic purpura after measles-mumps-rubella immunization in children. *Pediatrics* 2008; 121: e687-92.
- Johnsen J. Pathogenesis in immune thrombocytopenia: new insights. *Hematol Am Soc Hematol Educ Program* 2012; 2012: 306-12.
- Journeycake JM. Childhood immune thrombocytopenia: role of rituximab, recombinant thrombopoietin, and other new therapeutics. *Hematol Am Soc Hematol Educ Program* 2012; 2012: 444-9.
- Kuhne T, Buchanan GR, Zimmerman S, *et al.* A prospective comparative study of 2540 infants and children with newly diagnosed idiopathic thrombocytopenic purpura (ITP) from the Intercontinental Childhood ITP Study Group. *J Pediatr* 2003; 143: 605-8.
- Labarque V, Van Geet C. Clinical practice: immune thrombocytopenia in paediatrics. *Eur J Pediatr* 2014; 173: 163-72.
- Mantadakis E, Farmaki E, Buchanan GR. Thrombocytopenic purpura after measles-mumps-rubella vaccination: a systematic review of the literature and guidance for management. *J Pediatr* 2010; 156: 623-8.
- O'Leary ST, Glanz JM, McClure DL, *et al.* The risk of immune thrombocytopenic purpura after vaccination in children and adolescents. *Pediatrics* 2012; 129: 248-55.
- Sauvé LJ, Scheifele D. Do childhood vaccines cause thrombocytopenia? *Paediatr Child Health (Oxford)* 2009; 14: 31-2.
- Schlereth B, Rose JK, Buonocore L, ter Meulen V, Niewiesk S. Successful vaccine-induced seroconversion by single-dose immunization in the presence of measles virus-specific maternal antibodies. *J Virol* 2000; 74: 4652-7.
- Techasena W, Wongwacharapiboon P, Terawanich S, Pattamadilok S. A comparison study of measles antibody between two doses vaccination at 9, 18 months and single dose at 9 months in children 4-6 years old. *J Med Assoc Thai* 2011; 94: 309-15.
- Terrell DR, Beebe LA, Vesely SK, Neas BR, Segal JB, George JN. The incidence of immune thrombocytopenic purpura in children and adults: A critical review of published reports. *Am J Hematol* 2010; 85: 174-80.
- Vlacha V, Forman EN, Miron D, Peter G. Recurrent thrombocytopenic purpura after repeated measles mumps-rubella vaccination. *Pediatrics* 1996; 97: 738-9.
- Yong M, Schoonen WM, Li L, *et al.* Epidemiology of paediatric immune thrombocytopenia in the General Practice Research Database. *Br J Haematol* 2010; 149: 855-64.