

CASE REPORT

SEVERE PENTASTOMIASIS IN CHILDREN: A REPORT OF 2 CASES

Fang Ye¹, Zi-Ke Sheng², Jun-Jie Li³ and Ji-Fang Sheng³

¹Department of Child Healthcare, The Children's Hospital of School of Medicine, Zhejiang University, Hangzhou; ²Institute of Antibiotics, Huashan Hospital, Fudan University, Shanghai; ³State Key Laboratory for Diagnosis and Treatment of Infectious Diseases, The 1st Affiliated Hospital of School of Medicine, Zhejiang University, Hangzhou, China

Abstract. Pentastomiasis is a type of parasitic zoonosis. Most patients with pentastomiasis are asymptomatic. We report here two pediatric patients with severe pentastomiasis (porocephaliasis taiwan and armilliferiasis), and the results of their 6-year and 3-year follow-ups, respectively. The manifestations and outcomes of the two cases are described. The diagnoses were established by histopathologic and/or parasitologic examinations. After diagnosis, traditional Chinese medicine (TCM), as well as praziquantel and/or albendazole, were used for treatment. This report highlights the seriousness of pentastomiasis in children. We suggest TCM be considered as supplementary or even primary treatment of children with severe pentastomiasis.

Keywords: parasitic diseases, porocephaliasis, armilliferiasis, armillifer, traditional Chinese medicine

INTRODUCTION

Pentastomiasis is a parasitic zoonosis caused by pentastomids (tongue worms). Humans may serve as aberrant definitive hosts or accidental intermediate hosts (Koehsler *et al*, 2011). Most patients with visceral pentastomiasis are asymptomatic

or have a subclinical presentation (Ma *et al*, 2002; Yao *et al*, 2008). The diagnosis of pentastomiasis is usually incidental. The treatment of severe pentastomiasis is a challenge due to the lack of effective chemotherapeutic agents. Several pediatric cases of visceral pentastomiasis have been reported in China (Pan *et al*, 2005; Yao *et al*, 2008; Lai *et al*, 2010); some of which had life-threatening symptoms. However, data regarding the clinical manifestations of this disease in humans are limited, and outcomes are unknown. Herein, we summarize the clinical characterizations and outcomes of two pediatric cases of severe visceral pentastomiasis hospitalized at our institution.

Correspondence: Ji-Fang Sheng, Department of Infectious Disease, State Key Laboratory for Diagnosis and Treatment of Infectious Diseases, The 1st Affiliated Hospital of School of Medicine, Zhejiang University, 79 Qingchun Road, Hangzhou 310003, China.

Tel: +86 571 87236759; Fax: +86 571 87236755

E-mail: jifangsheng9200@163.com

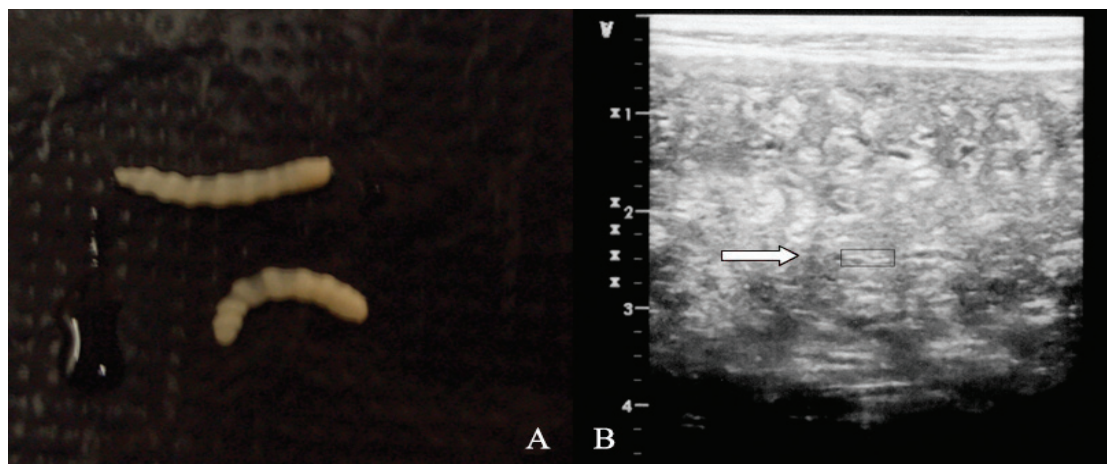


Fig 1—Morphology of *Armillifer agkistrodontis* and *Porocephalus taiwana* sp. nov. A) *A. agkistrodontis* from stool (1.50 cm x 0.36 cm). B). Abdominal ultrasonography revealed *P. taiwana* sp. nov. nymph in the liver (in rectangle, 0.43 cm x 0.05 cm).

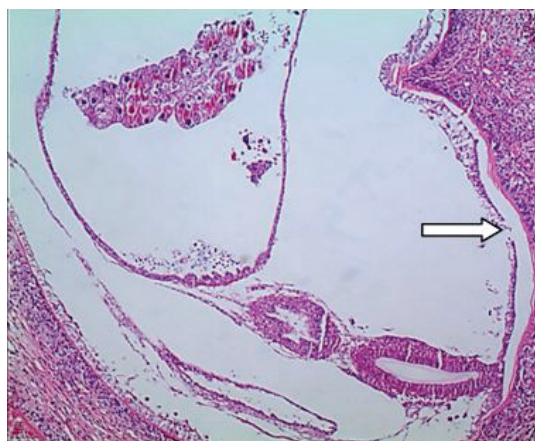


Fig 2—Pathological results of porocephalial infection in the bowel wall (*Porocephalus taiwana* sp. nov. in the bowel wall (arrow, hematoxylin and eosin stain, x100).

CASE REPORT

Case 1

A 13-year old boy, from Fuyang, Zhejiang Province, China was admitted to our hospital in January, 2006. He had paroxysmal fever and abdominal pain for about six months. His temperature was 38.5°C, respiratory rate was 24 breaths per

minute, blood pressure was 117/75 mmHg and his heart rate was 90 beats per minute. He had poor appetite and no vomiting.

On physical examination, he appeared ill, pale, and thin, with a weight of 23 kg. His abdomen was distended. He had a liver palpable 5 cm below the midclavicular line on this right; his spleen was not palpable. The cardiovascular, pulmonary, and nervous system examinations were normal. Laboratory tests showed a WBC count of $27.9 \times 10^9/l$ with 76.1% neutrophils, an eosinophil count of $5.48 \times 10^9/l$ (19.6%) and a hemoglobin of 93 g/l. The C-reactive protein (CRP) was 48 mg/l. The liver, renal, and thyroid function tests were normal and the blood culture was negative.

An abdominal ultrasound examination showed hepatomegaly with diffuse low-echo nodular lesions in the liver (Fig 1). A small amount of ascites was seen in the abdominal cavity. An exploratory was performed the third day after admission and miliary nodules were found on the surfaces of the omentum, liver and small

Table 1
Main compositions and dosages of traditional Chinese medicine formula prescribed to the two cases.

| Case | Composition and dosages |
|--------|---|
| Case 1 | Barley 10g; <i>Cyathula officinalis</i> 10g; Dandelion 10g; Ginseng 10g; Fructus Aurantii 10g; <i>Melia toosendan</i> 10g; Pericarpium Citri Reticulatae 5g; Radix bupleuri 10g; Rhizoma Corydalis 10g; white Herbaceous peony 10g |
| Case 2 | <i>Atractylodes macrocephala</i> 8g; Fructus Aurantii 6g; Pericarpium arecae 10g; Pericarpium Citri Reticulatae 3g; Radix pseudostellariae 10g; tuckahoe 10g; Pseudostellariae 10g; Rhizoma Alismatis 10g; Rhizoma Phragmitis 30g; Semen Coicis 15g; Smoked plum 6g |

intestine. Pathology of these nodules revealed they were parasitic granulomas (Fig 2). The pathogen was identified as *Porocephalus taiwana* sp. nov. Upon further questioning, the patient's parents revealed he had consumed uncooked snake gall bladder several months previously, which could have been how the patient contracted the parasite. *Porocephaliais taiwan* was the final diagnosis.

Traditional Chinese medicine (TCM) (Table 1) and mebendazole (100 mg BID) were given to the patient for 3 days; two weeks later the TCM and praziquantel were given for 6 days. During treatment, numerous parasites were found in the patient's feces. However, the patient's condition did not improve significantly and the eosinophil count remained high.

After being discharged from our hospital, only TCM was administered, as an antihelminthic to expel the worms; this was given for 2 years. Two months after being discharged, the symptoms improved. During the 2-year-period of treatment, the number of worms in the stool gradually reduced until they finally disappeared. The eosinophils count gradually improved and an ultrasound of the abdomen showed the foci in the liver had

calcified. No further lesions appeared during 6 years of follow-up. Today, the patient has a weight of 42.5 kg, a height of 164 cm, and has graduated from high school.

Case 2

A 40-month old girl, from Tonglu, Zhejiang Province, China was referred to our hospital in February, 2009, after 3 days of fever and abdominal pain. She had pyrexia to 40°C with paroxysmal pain in the abdomen. Upon admission the patient appeared acutely ill. Her weight was 15 kg and her temperature was 37.8°C. She had abdominal distension without tenderness. The liver was palpable but the spleen was not palpable. Laboratory tests showed a WBC count of $13.9 \times 10^9/l$ with 73.1% neutrophils, 21.8% lymphocytes, 4.0% eosinophils and a hemoglobin of 91 g/l. Her CRP was greater than 160 mg/l. Her liver function tests were normal, and blood and cerebrospinal fluid cultures were negative.

A CT scan of the chest revealed multiple nodules in the lungs and superior mediastinum lymphadenosis. An MRI of the abdomen showed diffuse nodular lesions in the liver, retroperitoneal lymphadenopathy and a small amount of ascites. Exploratory laparotomy was conducted.

Diffuse white nodules were found on the liver surface and peritoneum. Pathology revealed armilliferiasis. The parents gave a history of raw snake viscera consumption 3 months prior to admission.

Initially, praziquantel (150 mg, TID) and albendazole (200 mg, BID) were given to treat the armilliferiasis for 6 days. Pentastomids were observed in the stool (Fig 1), but the symptoms did not improve. TCM (Table 1) was used to expel the parasites. After receiving this treatment for 2 months, a large number of white parasites were found in the feces, and the patient's condition improved greatly.

TCM was given for 2 years and at 3 years follow-up no parasites were found in the feces. Laboratory tests showed that the complete blood count and liver function test were normal. The CRP was less than 1 mg/l and a CT of the chest and abdomen revealed no new nodules. Currently, the patient is healthy and continues with follow-up.

DISCUSSION

Human pentastomiasis is a rare and can be divided into 2 types: visceral and nasopharyngeal pentastomiasis. To date, 6 types of pentastomiasis have been described; (armilliferiasis, linguatulosis, sebekiosis, raillietiellosis, leiperiosis, and porocephaliasis), and 10 species of pentastomids have been reported (*Armillifer agkistrodontis*, *A. armillatus*, *A. grandis*, *A. moniliformis*, *Leiperia cincinnalis*, *Linguatula serrata*, *Porocephalus crotali*, *P. taiwana* sp. nov., *Raillietiella hemidactyli*, and *Sebekia* sp.) (Lai *et al*, 2010). We described two pediatric patients with serious porocephaliasis taiwan and armilliferiasis. The pathologic features of *P. taiwana* sp. nov. have been described previously (Qiu *et al*, 2005).

With visceral porocephaliasis taiwan and armilliferiasis, several organs and tissues can be involved, including the liver (most often), spleen, lungs, small intestine, and lymph nodes (Ma *et al*, 2002; Tappe *et al*, 2006). Machado *et al* (2006) described a case of pentastomiasis mimicking a liver tumor. Pentastomids have been reported to infect the heart, eye, and brain (Cagnard *et al*, 1979; Tappe and Buttner, 2009). The symptoms of human pentastomiasis depend on localization and migration of parasites (Tappe *et al*, 2006). Abdominal pain, diarrhea, and ascites are three common characteristics of these two types of pentastomiasis. Mulder (1989) reported a case of armilliferiasis with abdominal pain for 10 years. Fever, cough, vomiting, constipation, and abdominal distention are common. Hepatosplenomegaly and eosinophilia are also frequently found (Jisieike-Onuigbo *et al*, 2011).

Visceral pentastomiasis should be considered in the differential diagnosis of a child with abdominal pain. The diagnosis of visceral pentastomiasis is challenging, since most cases of visceral pentastomiasis are asymptomatic. Diagnosis depends mainly on histopathologic and parasitologic findings (Ma *et al*, 2002). A history of raw snake viscera consumption may be helpful to diagnose this disease, as in our cases. Therefore, taking a detailed medical history is important, as it can help lead to a timely diagnosis.

Praziquantel and albendazole have been used to treat pentastomiasis. These two agents were also prescribed to treat pentastomiasis in the cases reported here. One case of human pentastomiasis treated with mebendazole and ciprofloxacin for 10 days resulted in an uneventful recovery (Jisieike-Onuigbo *et al*, 2011). However, the treatment should be evaluated in more detail. Tappe and Buttner (2009) found no

treatment was necessary in asymptomatic pentastomiasis cases. However, severe pentastomiasis may lead to organ failure and even death (Ma *et al*, 2002; Yapo Ette *et al*, 2003; Jisieike-Onuigbo *et al*, 2011). Patients with severe pentastomiasis should be treated in a timely manner. Praziquantel and albendazole may be less than completely effective for the treatment of pentastomiasis. It is also important to enhance the host immune system and reduce the number of worms in critically ill patients. While most adult patients with pentastomiasis are asymptomatic, pediatric patients may have a severe infection. Incomplete development of the immune system may partially contribute to this fact.

In this report, the two cases were also treated with TCM. The composition of the TCM given to these two cases is shown in Table 1. However, the individualized treatment, as a main feature of TCM, makes the compositions and dosages of the drugs vary widely, depending on the individual condition. In spite of the fact the parasites were still degenerating after 2 years (Tappe and Buttner, 2009), we believe TCM played a positive role in the treatment of these pentastomiasis cases.

Many factors may have affected the outcomes of this disease, such as the host immune system, the number and type of parasites, the organ systems involved and the treatment. Focal parasitic involvement usually has a satisfactory prognosis (Machado *et al*, 2006), while disseminated involvement is often fatal (Obafunwa *et al*, 1992).

To prevent pentastomiasis, several measures should be implemented. First, food should be cooked properly, especially in regions where uncooked or undercooked viscera of animals are frequently

consumed. Second, a heightened awareness of foodborne diseases is necessary.

Our report highlights the importance of timely treatment of severe pentastomiasis in children using TCM as an antihelminthic, and adds new data about the outcomes of this disease. The present report is helpful for clinicians to recognize and treat this disease, especially in non-endemic areas.

ACKNOWLEDGEMENTS

We thank Ms Lo-Han Yuan and Ms Sandhya Kajeepeta for critically reading this manuscript. This work was supported financially by the Chinese High Tech Research and Development (863) Program (No. 2011AA020104), and the National Natural Science Foundation of China (NO. 30972592).

REFERENCES

- Cagnard V, Nicolas-Randegger J, Dago Akribi A, *et al*. [Generalized and lethal pentastomiasis due to *Armillifer grandis* (Hett, 1915)]. *Bull Soc Pathol Exot Filiales* 1979; 72: 345-52.
- Jisieike-Onuigbo NN, Odenigbo CU, Kalu OA, Eze KC. *Armillifer armillatus* infection. *Niger J Clin Pract* 2011; 14: 501-3.
- Koehsler M, Walochnik J, Georgopoulos M, *et al*. *Linguatula serrata* tongue worm in human eye, Austria. *Emerg Infect Dis* 2011; 17: 870-2.
- Lai C, Wang XQ, Lin L, *et al*. Imaging features of pediatric pentastomiasis infection: a case report. *Korean J Radiol* 2010; 11: 480-4.
- Ma KC, Qiu MH, Rong YL. Pathological differentiation of suspected cases of pentastomiasis in China. *Trop Med Int Health* 2002; 7: 166-77.
- Machado MA, Makdissi FF, Canedo LF, *et al*. Unusual case of pentastomiasis mimicking liver tumor. *J Gastroenterol Hepatol* 2006;

- 21: 1218-20.
- Mulder K. Porocephalosis. *Dtsch Med Wochenschr* 1989; 114: 1921-3.
- Obafunwa JO, Busuttill A, Nwana EJ. Sudden death due to disseminated porocephalosis—a case history. *Int J Legal Med* 1992; 105: 43-6.
- Pan CM, Tang HF, Qiu MH, Xiong QX. Heavy infection with *Armillifer moniliformis*: a case report. *Chin Med J (Engl)* 2005; 118: 262-4.
- Qiu MH, Ma KC, Fan PC, Lu SS. Discovery of a new species of the pentastomid genus *Porocephalus* (Humboldt, 1811) from Taiwan, China and its pathogenic features. *Chin J Parasitol Parasit Dis Apr* 2005; 23: 69-72 (in Chinese).
- Tappe D, Buttner DW. Diagnosis of human visceral pentastomiasis. *PLoS Negl Trop Dis* 2009; 3: e320.
- Tappe D, Winzer R, Buttner DW, et al. Linguatuli-asis in Germany. *Emerg Infect Dis* 2006; 12: 1034-6.
- Yao MH, Wu F, Tang LF. Human pentastomiasis in China: case report and literature review. *J Parasitol* 2008; 94: 1295-8.
- Yapo Ette H, Fanton L, Adou Bryn KD, Botti K, Koffi K, Malicier D. Human pentastomiasis discovered postmortem. *Forensic Sci Int* 2003; 137: 52-4.