

CASE REPORT

MYCOBACTERIUM SZULGAI LYMPHADENITIS MIMICKING KIKUCHI'S DISEASE IN THAILAND

Wirach Maek-a-nantawat¹ and Parnpen Viriyavejakul²

¹Department of Clinical Tropical Medicine, ²Department of Tropical Pathology,
Faculty of Tropical Medicine, Mahidol University, Bangkok, Thailand

Abstract. *Mycobacterium szulgai* is rarely found to be a cause of reported infection. Two thirds of cases were reported as pulmonary presentations, while the rest were infections of soft tissues or bone. In Thailand, few pulmonary infections due to *M. szulgai* have been reported. This is the first case of *M. szulgai* lymphadenitis confirmed by tissue culture. The patient presented with prolonged fever and tender enlarged cervical nodes. Histological findings showed large histiocytes with necrotic background compatible with Kikuchi's disease. However, the culture proved the case to be one of *M. szulgai* infection. That means this mycobacterium should be included in the differential diagnosis of fever with lymphadenitis.

In recent years, a number of newly identified organisms have been recorded as causes of infectious diseases. Among these agents, *Mycobacterium szulgai* has been known since 1972 as an unusual pathogen for lung infection in humans (Marks *et al*, 1972). From the first identification of this scotochromogenic mycobacterium by lipid analysis (Jenkins *et al*, 1972), there have been an increasing number of case reports from various parts of the world such as United States, Japan, Australia, Portugal and Britain (Maloney *et al*, 1987). In this AIDS era, with increasing incidence and awareness of pandemic co-infected tuberculosis, the uncommon non-tuberculous mycobacteria have been reported more frequently. The incidence of *M. szulgai* is scanty when compared to *M. tuberculosis* or other non-tuberculous mycobacteria, however most of the cases involved pulmonary infections (Yamamoto, 2000). In Thailand, only one case of *M. szulgai* infection

was mentioned in a review of non-tuberculous mycobacterial infection of the lung during 1969 to 1978 (Wongwatana and Sriyabhaya, 1992). We report a case of subacute lymphadenitis presenting as prolonged fever that is a rather rare clinical manifestation of *M. szulgai* infection which has not been mentioned before in Thai literature. Pathological review of a cervical lymph node was consistent with Kikuchi's disease. The infection was confirmed by tissue culture.

A 33 year-old married Thai man from Chainat came to the Hospital for Tropical Diseases, Bangkok with the complaint of 10-weeks fever. Firstly, he felt feverish and sore throat. After medical consultations at a nearby clinic, he was diagnosed as upper respiratory tract infection but was not improved by medications. Fever had been usually found in the evening or night time and was partially responsive to antipyretics. He observed that palpable lymph nodes at the cervical area spontaneously resolved but others recurred. Four weeks prior to this admission, the admission record in another hospital demonstrated high-grade fever with cervical lymphadenopathy and investigation results included leukopenia and mild anemia, normal chest roentgenogram and

Correspondence: Dr Wirach Maek-a-nantawat, Department of Clinical Tropical Medicine, Faculty of Tropical Medicine, Mahidol University, 420/6 Rajavithi Road, Bangkok 10400, Thailand.
Tel: (+66) 22455919, 22471957; Fax: (+66) 22471957
E-mail: tmwmk@mahidol.ac.th

echocardiogram, and negative anti-HIV serology. After one week of hospitalization, fever declined and disappeared spontaneously. Two weeks prior to his present admission, he developed fever with palpable cervical lymph nodes. No rash or arthralgia was evident. Past history did not reveal any significant diseases or risk of infection, *ie* no traveling, no pet or cattle exposure. He reported only a single sexual partner. Physical examination revealed high-grade fever (39.5°C) with cervical lymphadenitis. One prominent node was noted in the left side cervical area. No skin or other systemic abnormality was noted.

Complete blood count was done and revealed Hb 13.3 g/dl, WBC 4,100/mm³ (PMN 65%, L28%, Mono6%, Baso 1%), platelets 212,000/mm³ and erythrocyte sedimentation rate was 80 mm/hr. Urine analysis, chest roentgenogram and liver function tests were normal. Anti-HIV test was negative. Serology tests for Epstein Barr virus, herpes simplex virus, VDRL and rickettsial titer were all negative. Computerized tomography scan of abdomen was done to exclude infected pus collection or mass that could be a source of fever and the result was unremarkable with no intra-abdominal node seen. Cervical node biopsy was performed and also sent for culture. Imprint of the node revealed a cellular specimen with presence of cells of atypical appearance. Grossly, the specimen measured 1.5 x 1.5 x 1.5 cm³ and cut surfaces showed rubbery white-tan tissue. Microscopic evaluation of the node demonstrated partial effacement. Large histiocytes and necrotic background were noted. The histiocytes were admixed with immunoblasts and plasmacytoid cells. No organism was detected with special stains. The background consisted of karyorrhectic and karyolytic debris and absence of neutrophil infiltration (Fig 1). Kikuchi-Fujimoto disease was the provisional diagnosis.

Ibuprofen was given as symptomatic treatment for short period (1 week) and fever seemed to respond. The patient was discharged and came for follow-up 2 weeks later. He did not complain of fever and temperature was 37°C. No cervical lymph node was palpated. Complete blood count was rechecked and demon-

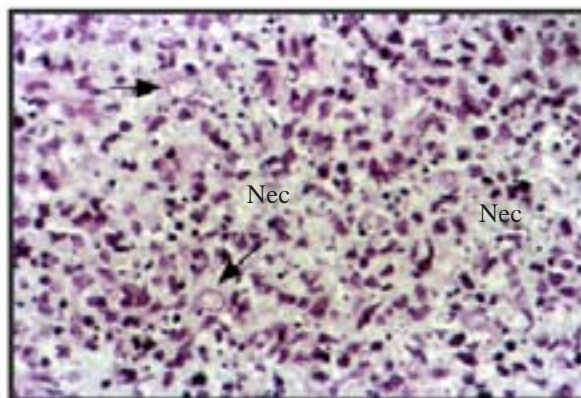


Fig. 1 A section from cervical lymph node consistent with Kikuchi's disease; showing necrotic background (Nec) devoid of neutrophils, a mixture of large cells like histiocytes (→) are seen. Hematoxylin and eosin stain, 400X.

strated Hb 12.7 g/dl, WBC 4,500 /mm³ (PMN 46%, L43%, Mono 8%, Baso 2%, Eos 1%), platelets 223,000/mm³. The lymph node culture showed the growth of *M. szulgai*. Antibiotic sensitivity testing demonstrated complete resistance to streptomycin, isoniazid, rifampicin and para-aminosalicylic acid but sensitivity to ethambutol and kanamycin. The patient looked well, without lymphadenopathy and complete blood count result showed normal WBC (5,500/mm³). He was not given any medication. At the last follow-up, 3 months after *Mycobacterium szulgai* infection was cultured, he looked well.

Prolonged fever with lymphadenopathy in this patient should be resulted from infection rather than other causes like malignancy or connective tissue disease because he had been healthy and developed this abrupt illness. The other clue supporting infectious process was local cervical adenitis. We excluded HIV infection based on the negative serology result. The differential diagnosis of such a case should include subacute to chronic infections such as infectious mononucleosis, tuberculosis, melioidosis, rickettsial infection, HSV and CMV infection. Malignancy (especially lymphoma), autoimmune diseases like Still's disease, sarcoidosis and histiocytic necrotizing lymphadenitis

denitis (Kikuchi's disease) might be added for differential diagnosis. Kikuchi's disease which was firstly described by Kikuchi *et al* (1972) and Fujimoto *et al* in 1972 is a self-limiting cause of lymphadenopathy with unknown etiology. The diagnosis is based on histologic examination characterized by paracortical necrotizing lymphohistiocytic foci without granulocytic infiltration (Thongsuksai *et al*, 1999). The pathologic finding of abundant large histiocytes with necrotic debris from cervical node in this case is consistent with Kikuchi's disease if other infections were excluded (Kuo, 1995; Thongsuksai *et al*, 1999; Tsang *et al*, 1994). Although all staining (AFB, Warthin's stain) of node imprint and tissue sections were negative, culture did reveal a causal organism. So tissue culture should be encouraged to prove or exclude infection.

Mycobacterium zulgai was firstly reported as new pathogen in humans in 1972 with a following report of 7 infected patients in the same year (Jenkins *et al*, 1972; Marks *et al*, 1972). Until now, its epidemiology has been difficult to identify but there have been more than 30 cumulative cases published worldwide (Davidson, 1976; Dylewski *et al*, 1987; Frueh *et al*, 2000; Horusitzky *et al*, 2000; Hurr and Sorg, 1998; Maloney *et al*, 1987; Nakayama *et al*, 2000; Zenone *et al*, 1999). More frequently reports have come from Japan since the first presentation. *M. zulgai* is one of scotochromogens (Runyon GrII), found in less than 1% of all human isolates (Dylewski *et al*, 1987). In Japan, Akita *et al* reported in 1999 that this agent represents about 2.4% of all non-tuberculosis mycobacteria isolated. At least two thirds of cases presented with pulmonary problems mimicking pulmonary tuberculosis (Davidson, 1976; Maloney *et al*, 1987). There have been some reports of soft tissue or bone infection in HIV infected patients (Luque *et al*, 1998) but rarely has adenitis been mentioned. In Thailand, *M. zulgai* has been reported to be a rare cause of mycobacterium infection in lung (Wongwatana and Sriyabhaya, 1992) but this is the first case report of *M. zulgai* adenitis.

Regarding the specific treatment, there is

no standard recommendation at present. Some data demonstrated that this agent is more sensitive to antituberculous drugs like rifampicin than other nontuberculous mycobacteria such as *Mycobacterium avium complex* and also is responsive to macrolides like clarithromycin (Shimizu *et al*, 2000). Hence, common antituberculous drugs such as isoniazid, ethambutol, pyrazinamide can be used as the treatment and should be given in the case of pulmonary infection for prolonged duration of up to 12-18 months. These drugs, however, was not given to this patient since his clinical symptoms improved after node excision.

ACKNOWLEDGEMENTS

The publication of this paper is supported by the Faculty of Tropical Medicine, Mahidol University, Thailand.

REFERENCES

- Akita Y, Nishio M, Maeno K, *et al*. Nontuberculous mycobacterial disease in a general hospital. *Kekkaku* 1999; 74: 107-13.
- Davidson PT. *Mycobacterium zulgai*: A new pathogen causing infection of the lung. *Chest* 1976; 69: 799-801.
- Dylewski JS, Zackon HM, Latour AH, Berry GR. *Mycobacterium zulgai*: An unusual pathogen. *Rev Infect Dis* 1987; 9: 578-80.
- Frueh BE, Dubuis O, Imesch P, Bohnke M, Bodmer T. *Mycobacterium zulgai* keratitis. *Arch Ophthalmol* 2000; 118: 1123-4.
- Fujimoto Y, Kojima Y, Yamaguchi K. Cervical subacute necrotizing lymphadenitis. *Naika* 1972; 30: 920-7.
- Horusitzky A, Puechal X, Dumont D, Begue T, Robineau M, Boissier MC. Carpal tunnel syndrome caused by *Mycobacterium zulgai*. *J Rheumatol* 2000; 27: 1299-302.
- Hurr H, Sorg T. *Mycobacterium zulgai* osteomyelitis. *J Infect* 1998; 37: 191-2.
- Jenkins PA, Marks J, Schaefer WB. Thin-layer chromatography of mycobacterial lipids as an aid to classification: the scotochromogenic mycobac-

- teria, including *Mycobacterium scrofulaceum*, *M. xenopi*, *M. aquae*, *M. gordonae*, *M. flavescens*. *Tubercle* 1972; 53: 118-27.
- Kikuchi M. Lymphadenitis showing focal reticulum cervical hyperplasia with nuclear debris and phagocyte. *Acta Hematol Jpn* 1972; 35: 379-80.
- Kuo TT. Kikuchi's disease (Histiocytic necrotizing lymphadenitis). A clinicopathologic study of 79 cases with an analysis of histologic subtypes, immunohistology and DNA ploidy. *Am J Surg Pathol* 1995; 19: 798-809.
- Luque AE, Kaminski D, Reichman R, Hardy D. *Mycobacterium szulgai* osteomyelitis in an AIDS patient. *Scand J Infect Dis* 1998; 30: 88-91.
- Maloney JM, Gregg CR, Stephens DS, Manian FA, Rimland D. Infections caused by *Mycobacterium szulgai* in humans. *Rev Infect Dis* 1987; 9: 1120-6.
- Marks J, Jenkins PA, Tsukamura M. *Mycobacterium szulgai*-a new pathogen. *Tubercle* 1972; 53: 210-4.
- Nakayama S, Fujii T, Kadota J, *et al*. Pulmonary mycobacteriosis caused by rifampicin-resistant *Mycobacterium szulgai*. *Intern Med* 2000; 39: 309-12.
- Shimizu T, Kodama K, Kobayashi H, Ohkawara A, Ogawa K, Tanijuchi S. Successful treatment using clarithromycin for cutaneous lesion caused by *Mycobacterium szulgai*. *Br J Dermatol* 2000; 142: 834-40.
- Thongsuksai P, Kayasut K. Histiocytic necrotizing lymphadenitis (Kikuchi's diseases): Clinicopathologic characteristics of 23 cases and literature review. *J Med Assoc Thai* 1999; 82: 812-8.
- Tsang WYW, Chan JKC, Ng CS. Kikuchi's lymphadenitis: A morphologic analysis of 75 cases with special reference to unusual features. *Am J Surg Pathol* 1994; 18: 219-31.
- Wongwatana S, Sriyabhaya N. Non tuberculous mycobacterial infection of the lung in a Chest Hospital in Thailand. *J Med Assoc Thai* 1992; 75: 1-10.
- Yamamoto M. Pulmonary diseases due to *Mycobacterium szulgai* in Japan. *Intern Med* 2000; 39: 277-9.
- Zenone T, Boibieux A, Tigaud S, *et al*. Non tuberculous mycobacterial tenosynovitis; A review. *Scand J Infect Dis* 1999; 31: 221-8.